REVIEW ARTICLE

# Roles of the medial and lateral orbitofrontal cortex in major depression and its treatment

Bei Zhang[1,2,11], Edmund T. Rolls[1,3,4,11]✉, Xiang Wang[5,6,7], Chao Xie[1,2], Wei Cheng[1,2,8,9]✉ and Jianfeng Feng[1,2,4,8,10]✉

© The Author(s), under exclusive licence to Springer Nature Limited 2024

We describe evidence for dissociable roles of the medial and lateral orbitofrontal cortex (OFC) in major depressive disorder (MDD) from structure, functional activation, functional connectivity, metabolism, and neurochemical systems. The reward-related medial orbitofrontal cortex has *lower* connectivity and *less* reward sensitivity in MDD associated with anhedonia symptoms; and the non-reward related lateral OFC has *higher* functional connectivity and *more* sensitivity to non-reward/aversive stimuli in MDD associated with negative bias symptoms. Importantly, we propose that conventional antidepressants act to normalize the hyperactive lateral (but not medial) OFC to reduce negative bias in MDD; while other treatments are needed to operate on the medial OFC to reduce anhedonia, with emerging evidence suggesting that ketamine may act in this way. The orbitofrontal cortex is the key cortical region in emotion and reward, and the current review presents much new evidence about the different ways that the medial and lateral OFC are involved in MDD.

*Molecular Psychiatry* (2024) 29:914–928; https://doi.org/10.1038/s41380-023-02380-w

## INTRODUCTION TO THE ORBITOFRONTAL CORTEX (OFC) AND DEPRESSION

### Introduction

Major depressive disorder (MDD) is a prevalent and debilitating psychiatric disorder associated with high rates of suicide and significant family and social burdens [1, 2]. Nearly one-third of depressed patients fail to respond to current antidepressant medication, adding to the devastating nature of the disorder [3]. Clinically, MDD is a heterogeneous disease that typically is accompanied by symptoms such as anhedonia (i.e., amotivation and loss of interest/pleasure), depressed mood (i.e., feelings of sadness), rumination, diminished concentration (i.e., deficits in attention and memory), and thoughts of death/suicide.

In this paper, we take the approach of considering the key brain region involved in emotion in humans, the orbitofrontal cortex [4, 5], and show that the OFC is a key region involved in MDD, and present the implications for treatments. In particular, we show that the human lateral orbitofrontal cortex is involved in responses to not receiving expected reward, and that the lateral OFC has higher connectivity and more activations to non-reward/aversive stimuli in MDD, which is related to the negative bias symptom and can be ameliorated by conventional antidepressants such as selective serotonin reuptake inhibitors (SSRIs). We further show that the medial orbitofrontal cortex is involved in responses to rewards, and has lower connectivity and responses to reward in MDD which is more associated with the anhedonia symptoms. We show that the medial OFC is not normalized by conventional antidepressants, and propose that new treatments are needed that operate on the medial orbitofrontal cortex. One such possible treatment is ketamine, and another is deep brain stimulation. The focus of this paper is on the evidence implicating the lateral and medial orbitofrontal cortex in different ways in depression, but we start with an overview about how the orbitofrontal cortex is involved in emotion in humans.

### Anatomy and subdivisions of the orbitofrontal cortex

The OFC is a cortical area on the ventral surface of the frontal lobe in humans and other primates. On the basis of cytoarchitectural characteristics, the human OFC includes two main cortical areas shown in Figs. 1A, S1 and S2, the medial OFC 11 and 13, and lateral OFC 47/12 [6–8]. The cytoarchitecture of the OFC in the human brain has the same overall architectonic pattern as that of the macaque brain [9]. According to the meta-analysis in Kringelbach (2005), the lateral OFC 47/12 has x-axis MNI coordinates from −33 to −55 and from 33 to 55, and the medial OFC 13 and 11 has x-axis coordinates between −33 and 33 [10]. The orbitofrontal cortex has connections to the ventromedial prefrontal cortex (vmPFC) (which includes parts of area 10) and to the anterior cingulate cortex (ACC) on the medial wall of the hemisphere (Figs. 1A, S1 and S2), as shown by connection studies in macaques and humans [9, 11].

[1]Institute of Science and Technology for Brain-Inspired Intelligence, Fudan University, Shanghai, PR China. [2]Key Laboratory of Computational Neuroscience and Brain-Inspired Intelligence (Fudan University), Ministry of Education, Shanghai, PR China. [3]Oxford Centre for Computational Neuroscience, Oxford, UK. [4]Department of Computer Science, University of Warwick, Coventry, UK. [5]Medical Psychological Center, The Second Xiangya Hospital, Central South University, Changsha, PR China. [6]Medical Psychological Institute, Central South University, Changsha, PR China. [7]China National Clinical Research Center on Mental Disorders (Xiangya), Changsha, PR China. [8]MOE Frontiers Center for Brain Science, Fudan University, Shanghai, PR China. [9]Department of Neurology, Huashan Hospital, Fudan University, Shanghai, PR China. [10]Zhangjiang Fudan International Innovation Center, Shanghai, PR China. [11]These authors contributed equally: Bei Zhang, Edmund T. Rolls. ✉email: Edmund.Rolls@oxcns.org; wcheng@fudan.edu.cn; jffeng@fudan.edu.cn

Received: 25 June 2023 Revised: 6 December 2023 Accepted: 13 December 2023
Published online: 12 January 2024

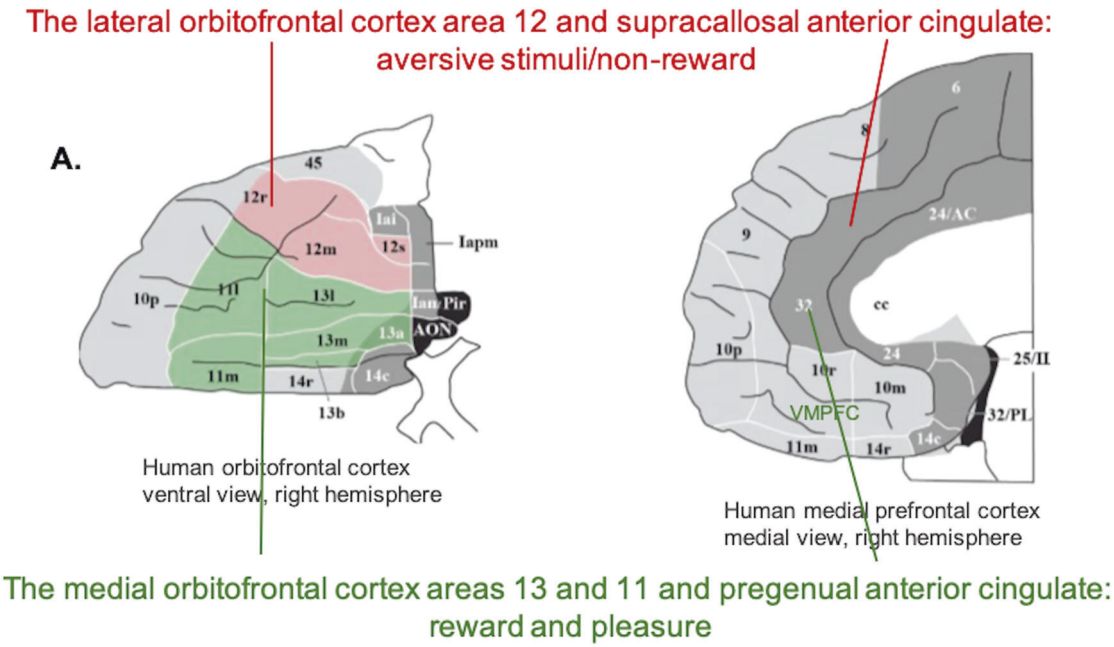


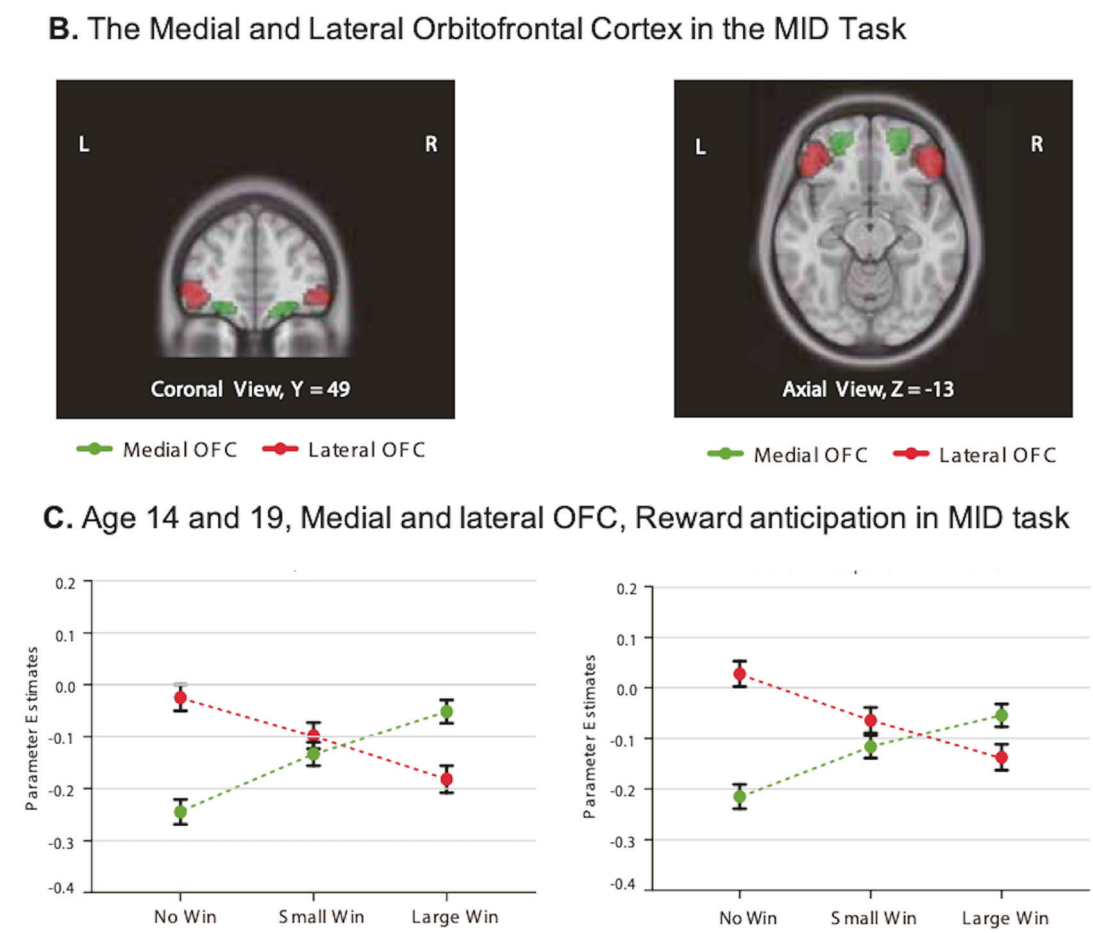


**Functional specialization of the human medial and lateral orbitofrontal cortex**

The OFC is the key brain area in humans involved in emotion, where emotions can be analyzed as states elicited by rewards that are associated with pleasure, and by punishers or non-reward that are associated with unpleasant feelings [4, 5, 8, 12]. A foundation is provided by single neuron recording studies in macaques which show *that* primary (unlearned) rewards and punishers such as taste activate some OFC neurons [13], *that* some neurons learn in 1 or 2 trials to associate visual or olfactory stimuli with these

**Fig. 1 Anatomy and functional specialization of the human medial and lateral OFC. A** Maps of architectonic areas in the human orbitofrontal cortex (left, ventral view of the brain) and medial prefrontal cortex including anterior cingulate cortex (right, medial view of the brain) of humans. Left: The medial orbitofrontal cortex includes areas 13 and 11 (green). The lateral orbitofrontal cortex includes area 12 (red). (Area 12 is sometimes termed area 12/47 in humans. The figure shows two architectonic subdivisions of area 12.) Almost all of the human orbitofrontal cortex except area 13a is granular. Agranular cortex is shown in dark grey. The part of area 45 shown is the orbital part of the inferior frontal gyrus pars triangularis. Right: the anterior cingulate cortex includes the parts shown of areas 32, 25 (subgenual cingulate), and 24. The ventromedial prefrontal cortex includes areas 14 (gyrus rectus) 10m and 10r. AON: anterior olfactory nucleus; Iai, Ial, Iam, Iapm: subdivisions of the agranular insular cortex. (Modified from Ongür D, Ferry AT, and Price JL, Architectonic subdivision of the human orbital and medial prefrontal cortex. Journal of Comparative Neurology, 2003, 460:425–449, with permission from John Wiley and Sons [6]). **B** The lateral orbitofrontal cortex (red) is activated by not winning, and the medial orbitofrontal cortex (green) by winning, in the monetary incentive delay (MID) task. **C** The lateral orbitofrontal cortex region in which activations increased towards no reward (No Win) in the MID task are shown in red at age 14 (left panel) and 19 (right panel). The medial orbitofrontal cortex region in which activations increased with increasing reward from No Win to Small Win to High Win is shown in green at age 14 (left panel) and 19 (right panel). (Based on investigations in more than 1000 participants, and **B** and **C** modified from Xie C et al, Reward versus nonreward sensitivity of the medial versus lateral orbitofrontal cortex relates to the severity of depressive symptoms, Biological Psychiatry: Cognitive Neuroscience and Neuroimaging, 2021, 6(3):259–269, with permission from Elsevier [33]).

primary rewards, and to reverse the association in 1 trial [14], *that* these neurons only respond when these stimuli are rewarding as shown by feeding to satiety ('devaluation') [15], and *that* some of these neurons represent economic value as shown by the tradeoff between the amount of the reward and its quality [16, 17]. In addition, some other OFC neurons respond to non-reward, that is when an expected reward is not obtained [18, 19] (Fig. S3B). Consistent with this, lesions of the macaque OFC impair the selection of food reward stimuli and stimulus-reward association learning [20] (which was described as a problem with credit assignment [21]). This foundational evidence is described in more detail elsewhere [5].

This research has been extended to humans in neuroimaging investigations which show topological differences (beyond what is known in non-human primates) in that many rewards are represented in the medial OFC, and non-reward and aversive stimuli in the lateral OFC, and moreover these activations are correlated with the reported subjective pleasantness or unpleasantness (Fig. 1B). Evidence of this type has been found for olfactory [22], water [23], taste [24, 25], flavor and fat texture [26, 27], and pleasant vs. painful touch [28, 29] and thermal stimuli [30, 31]. This has been extended to more abstract types of reward, such as winning money which activates the medial OFC and losing money or not winning which activates the lateral OFC [32–34], and extended to beauty and face attractiveness [35] and amphetamine which activate the medial orbitofrontal cortex [36]. In addition, and importantly in relation to depression, it has been shown that not receiving an expected reward (non-reward), in for example a reward reversal task, activates the lateral OFC [34, 37] (Fig. S3A). A summary of the medial OFC activations produced by pleasant rewarding stimuli, and of the lateral OFC activations produced by unpleasant or non-reward events, is provided in Fig. 2 of Grabenhorst and Rolls [38]. Of note, the finding that the OFC is activated in relation to hidden variables that are relevant to decoding reward value and choice [39, 40] in no way negates but rather is consistent with all of this evidence about reward value representations in the orbitofrontal cortex. A more anterior and ventromedial prefrontal cortex region, vmPFC, is implicated by neuroimaging evidence in making choices between rewarded stimuli using attractor decision-making networks [41–43].

Consistent with this neuroimaging evidence, damage to the human OFC impairs subjectively experienced emotion, the evaluation of the emotional signal provided by face and voice expression, and reward reversal learning by impairing the change of behavior when non-reward is received for a choice and the behavior should switch to the alternative stimulus [44–47]. The hypothesis, based on the neuroimaging and lesion evidence in humans, is that the lateral OFC is activated by not receiving an expected reward (non-reward), and that lesions of the lateral OFC impair the ability to learn associations between stimuli and especially non-reward to guide their future choices of stimuli [5]. In contrast, the medial OFC represents reward value, and its activations are related to subjective pleasantness [5]. A related approach suggested that the medial and lateral OFC are involved in different components of value-guided behaviors, with the lateral OFC involved in credit assignment and the medial OFC in decision-making [48]. This actually aligns with our analysis [5]. Damage to the human lateral OFC was described as impairing the learning of associations between a visual stimulus and whether a reward had or had not just been received for that choice (and was described as a problem with 'credit assignment' [48]). Conversely, damage to the human medial OFC /vmPFC made reward choices more variable when more stimuli were available [48], in line with the evidence that the medial OFC is involved in choice decision-making between stimuli of different reward values in which noise in attractor networks is important [41–43].

Despite strong evidence for anatomic and functional heterogeneity within the OFC, some studies have treated this region as a unified whole. These investigations have often drawn upon observations from patients with brain damage and from animals subjected to similar experimental lesions, as highlighted in recent reviews [40, 49]. For instance, Rudebeck and Rich (2018) suggested that the OFC plays a pivotal role at the intersection of emotion and cognition [49]. The OFC was suggested to be involved in a complex set of cognitive mechanisms related to goal-directed behavior, encompassing the encoding, storage, and updating of the subjective value of cues, making prediction for potential outcomes, comparing values of different options for decision-making, evaluating the actual outcome, and using this information to determine if the outcome was better or worse to guide future decisions [49]. Another review (Knudsen and Wallis (2020)) compared a value hypothesis and a cognitive map hypothesis [40]. The former emphasizes the OFC's crucial role in value-guided behavior, particularly in signaling value. In contrast, the latter argues that the OFC may have a broader role in cognition by representing cognitive maps that guide behavior, with value being one of the many variables important for behavioral control. Our proposal, which distinguishes between the medial and lateral OFC in a reward and non-reward/punishment framework, describes functional differentiation within the OFC, and importantly, proposes how this differentiation is associated with different symptoms of MDD.

## Connectivity of the human orbitofrontal cortex

Advances have recently been made in understanding the connectivity of the human orbitofrontal cortex, by measuring the human orbitofrontal cortex effective (causal, directed) connectivity, functional connectivity, and anatomical connections with diffusion tractography [11, 12]. This connectivity is summarized in the Supplementary Material (Figs. S1 and S2, and in Figs. 2

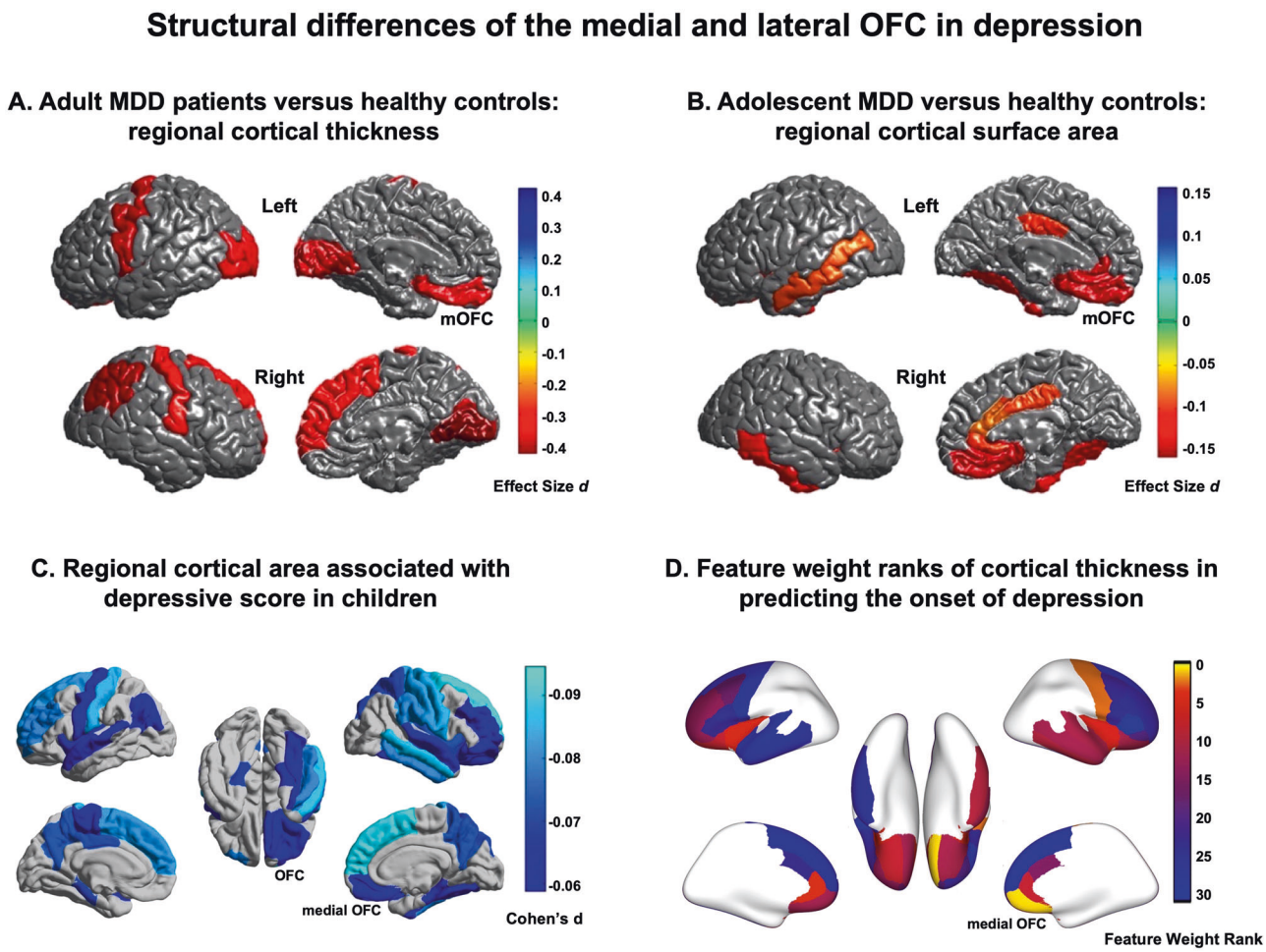


**Fig. 2 Structure abnormalities of the medial and lateral OFC related to depression.** Lower OFC cortical thickness and surface area in clinical depression (**A**, **B**); and associations between cortical area and thickness of the OFC and depressive symptoms in healthy and high-risk depression groups (**C**, **D**). **A** In the largest study on cortical structural alterations in MDD (by the ENIGMA consortium), the medial OFC/ventromedial prefrontal cortex (mOFC) exhibited the most significant gray matter thinning in adult MDD, followed by the rostral anterior cingulate cortex, posterior cingulate cortex, and lateral OFC. **B** The medial OFC/ventromedial prefrontal cortex had significant surface area reductions in adolescent MDD (**A** and **B**, reproduced with permission from Schmaal L et al., Cortical abnormalities in adults and adolescents with major depression based on brain scans from 20 cohorts worldwide in the ENIGMA Major Depressive Disorder Working Group. Molecular Psychiatry, 2017, 22(6):900–909, Springer Nature, Open Access [73]). **C** Gray matter volume of the medial and lateral OFC was negatively correlated with self-reported depressive scores in children (Modified with permission from Cheng W et al., Sleep duration, brain structure, and psychiatric and cognitive problems in children. Molecular Psychiatry, 2021, 26:3992–4003, Springer Nature [85]). **D** In a prospective study of healthy adolescent girls with a family history of MDD, cortical thickness in the medial OFC measured at baseline had the greatest weight in predicting the onset of future depression in all 32 brain regions (Modified from Foland-Ross LC et al., Cortical thickness predicts the first onset of major depression in adolescence, International Journal of Developmental Neuroscience, 2015, 46:125–31, with permission from John Wiley and Sons [88]).

and 3 of [5]), and shows how taste, somatosensory, visual and olfactory inputs reach the human orbitofrontal cortex, and how key outputs are to the anterior cingulate cortex for action-outcome learning; to the striatum and dopamine neurons for habit learning; to the hippocampal memory system to enable emotional states to be incorporated into episodic memory, to influence memory consolidation, and to provide the goals for navigation [50]; and to language regions which may be relevant to declarations about subjective emotional states [11, 12]. The current review aims to provide insight into the role of OFC subregions in depression, and further evidence on the connectivity and functions of the OFC is described elsewhere [5, 7, 8, 10, 12, 49, 51–54].

### Relation of the orbitofrontal cortex to other brain regions involved in emotion in humans

The orbitofrontal cortex has connectivity with the amygdala, an evolutionarily much older region [5]. In humans, many of the cortical regions that connect with the orbitofrontal cortex also connect to the amygdala, but the return connectivity back to the cortex from the amygdala is much weaker [5, 12], with amygdala connectivity to the brainstem implicated in behavioral responses to emotion-related stimuli. Consistent with this, the amygdala appears to be much less important in subjective emotional feelings than the orbitofrontal cortex, as evidenced by the minor changes in emotional experience following damage to the amygdala [5, 55–57]. In addition, the connectivity of the human orbitofrontal cortex to the pregenual anterior cingulate cortex provides a route for emotion-related stimuli (rewards and punishers) to reach the hippocampus for episodic memory and navigation to goals [5, 11]. The connectivity of the human orbitofrontal cortex to the supracallosal (dorsal) anterior cingulate cortex provides a route for actions to be learned to obtain the rewards or avoid the punishers represented in the orbitofrontal cortex [5, 11, 21]. The connectivity of the orbitofrontal cortex to the subgenual cingulate cortex may be involved in autonomic

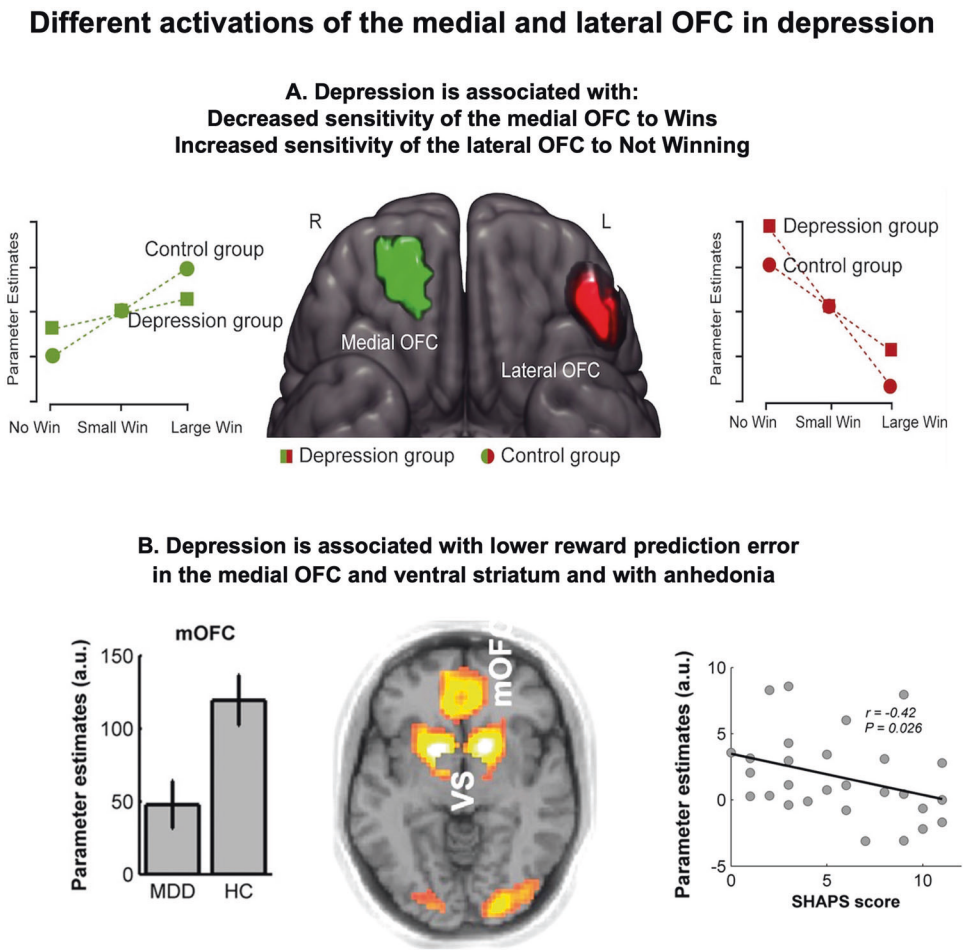


**Fig. 3 Disrupted medial and lateral OFC activation in distinct subcomponents of reward-related processing. A** Reward anticipation: Individuals with high-severity depressive symptom scores (squares) had reduced sensitivity of the medial OFC (highlighted in green) to reward cues, and enhanced sensitivity of the lateral OFC (highlighted in red) to non-reward cues relative to healthy controls (circles) during reward anticipation in a monetary incentive delay task (with permission from Elsevier [33], see above). **B** Reward prediction error: MDD patients had decreased medial OFC (mOFC) and ventral striatum (VS) neural responses compared to healthy controls when receiving unexpected reward feedback, and the reward prediction error neural signals in the medial OFC were inversely correlated with the degree of anhedonia (Snaith-Hamilton Pleasure Scale, SHAPS score) in depressed patients (Modified from Rothkirch M et al., Neural mechanisms of reinforcement learning in unmedicated patients with major depressive disorder, Brain, 2017, 140(4):1147–1157, with permission from Oxford University Press [106]).

responses [5], but this is a site where brain stimulation may alleviate depression [58], perhaps by activating the orbitofrontal cortex. Furthermore, the connectivity of the orbitofrontal cortex to the striatum may be involved in learned habit responses to emotion-related stimuli [5]. The connectivity of the orbitofrontal cortex to the ventral striatum (VS) with the onward connectivity in part via the habenula provides a route for reward and punishment to reach the brainstem dopamine neurons that may thereby signal reward prediction error for reinforcement learning [59–62]. The orbitofrontal cortex also connects to the frontal pole cortex, and the theory is that this provides evidence about rewards that are available for the decision about whether to exploit the current reward, or explore for possible better rewards [63]. Thus, the OFC is a crucial brain region in human emotion partly because it communicates emotion-related reward and punishment signals to other brain regions [5].

## An approach to the orbitofrontal cortex and major depressive disorder

Given the evidence that the OFC is a key brain region in emotion and reward, the theory was proposed that the lateral orbitofrontal cortex is involved in depression by being over-responsive to not receiving expected rewards (which induces sadness); and that the medial orbitofrontal cortex is involved in depression by being less responsive to rewards, and could contribute to anhedonia and less happiness [64]. Following up this theory, it was found in a large-scale resting-state functional connectivity (rsFC) study that there is higher connectivity of the lateral OFC with the precuneus and language-related regions in depression, and lower connectivity of the medial OFC with medial temporal lobe memory-related brain regions in depression [65]. That was followed up in a number of further investigations which showed that only the higher functional connectivity of the lateral OFC (but not the lower functional connectivity of the medial OFC) in MDD could be ameliorated by antidepressant drugs such as SSRIs [66–71]. A further investigation showed increased sensitivity to non-reward (not winning in a monetary incentive delay (MID) task) of the lateral OFC related to symptoms of depression such as negative feelings, and low sensitivity to the reward of winning in the medial OFC [33]. These findings are consistent with earlier evidence for a role of the OFC in the pathophysiology of MDD [72], with for example marked structural reduction (i.e., cortical thickness) in the OFC regions in depression [73]. There is also emerging evidence that the lateral OFC is a potential therapeutic target in brain

stimulation for depression patients [74–76]. In light of these findings, a detailed and comprehensive review concerning the separable roles of the medial and lateral OFC in major depression is of importance.

## DIFFERENCES OF THE ORBITOFRONTAL CORTEX RELATED TO DEPRESSION

### Structural differences of the orbitofrontal cortex in major depressive disorder

The OFC has structural differences, for example in volume and surface area, in depression. Initial evidence from postmortem studies in MDD showed reductions in the density and size of neurons in the OFC [77, 78]. Neuroimaging studies reported reduced gray matter volume [79, 80], cortical thinning [81], and lower surface area [73] of the medial OFC/ventromedial prefrontal cortex in MDD. With respect to distinct subregions of the OFC, the medial OFC is especially involved in MDD [73, 79, 81–83]. Many studies reported that smaller gray matter volume of the medial OFC (but not lateral OFC) significantly correlated with higher depression symptoms [82, 84] across MDD patients and healthy controls. A recent large study (1902 MDD patients and 7658 healthy controls) by the ENIGMA consortium showed that the brain regions with the strongest effect sizes for cortical gray matter thinning related to MDD were the medial OFC/ventromedial prefrontal cortex for adult MDD patients, followed by the rostral anterior cingulate cortex (rACC), posterior cingulate cortex (PCC), lateral OFC, insula, and fusiform gyrus [73] (Fig. 2A). This study also found that adolescents with MDD had a significantly lower surface area for the medial OFC / ventromedial prefrontal cortex, with also some reduction for the lateral OFC (Fig. 2B). Lower volume of the medial OFC was also reported in elderly patients with MDD in other studies [80, 83].

In addition to the structural abnormalities of the medial and lateral OFC found in clinical populations at different stages (i.e., first-episode, current, and remission), a negative association has also been found between morphological features of the OFC (in particular the medial OFC) with depressive symptoms in populations that have not been diagnosed with depression, and in young populations with a high-risk of depression, as follows. A recent large-scale Adolescent Brain Cognitive Developmental (ABCD) study (11,067 children aged 9–11) indicated that lower volume of the medial and lateral OFC was associated with higher self-reported depressive scores [85] (Fig. 2C). Moreover, a series of studies with the ABCD cohort showed that factors that were linked with depressive problems, such as lower sleep duration [85], higher family conflict [86], and lower maternal age [87], were also associated with lower volume in the medial and lateral OFC. All these studies provide evidence that structural alterations of the OFC are important vulnerability indicators for developing depression. In support of this idea, a prospective study evaluated healthy adolescent girls (10–15 years old) with a family history of MDD and showed that cortical thickness measured at baseline could predict the future onset of depression in a multivariate model, with the largest weights in the medial OFC relative to the lateral OFC and other non-OFC cortical areas [88] (Fig. 2D).

### Activation differences of the orbitofrontal cortex in major depressive disorder: implications for clinical features

In the context of the dissociable roles of the medial and lateral OFC in value-guided behavior and emotion, task-based neuroimaging studies provide evidence that dysfunctional activations in the medial and/or lateral OFC in MDD are associated with abnormalities in the different components of reward-related and emotional processing. In the next section, we focus on how activation differences in the medial and/or lateral OFC are linked to the clinical features found in MDD.

*Reward-related processing, the medial orbitofrontal cortex, and anhedonia*. The clinical and preclinical literature provides evidence that abnormalities in the OFC are linked to deficits in different subdomains of reward-related processing, such as reward anticipation, reward outcome, reward prediction error (PE), and decision-making (see reviews [89–93]). Based on current concepts, abnormalities in any of these subdomains in reward processing may lead to behaviors that can be interpreted as an anhedonia syndrome in MDD [89, 94, 95]. Indeed, abnormalities of the OFC have been strongly associated with the multidimensional anhedonia syndrome in MDD. For example, in the large-scale UK Biobank sample, the polygenic risk for the anhedonia symptoms was related to smaller volumes of brain reward circuits, such as smaller OFC volume [96]. In the next section, we summarize how abnormal OFC activations (in particular the medial OFC) related to components of reward processing are associated with different clinical symptoms such as amotivation, loss of interest/pleasure, and blunted associative learning, which contribute to anhedonia symptoms in depression.

Reward anticipation and amotivation in major depressive disorder: In addition to the consistent finding that blunted neural responses in the ventral striatum /nucleus accumbens (NAcc) are involved in deficits in reward anticipation [97, 98], hypoactivation of the OFC (which projects to the VS) also plays a crucial role in the anticipation of rewards in depressed states. Using the monetary incentive delay task, medication-free adult depressed patients exhibited weaker activations in the VS, medial OFC (peak coordinates: 33, 51, −3), and rostral ACC when anticipating high rewards relative to healthy controls, and the activations in the OFC and NAcc were positively correlated with the self-reported hedonic capacity in patients [99]. In line with this finding, blunted medial OFC activation in the reward anticipation phase was also found in medicated adult depressed patients [100], medicated adolescent depressed patients [101], and adolescent individuals with high-severity depression symptoms [33].

Of particular importance, a large-scale IMAGEN cohort study with 1877 individuals at the age of 14 and 1140 individuals at the age of 19 found that the medial OFC and VS were sensitive in a monetary incentive delay task to reward anticipation (reflected by graded activation increases from no- to small- to large-wins); and that the lateral OFC was sensitive to non-reward anticipation (reflected by graded activation increases from large- to small- to no-wins) [33] (Fig. 3). This provides evidence that the medial OFC is related to winning, and the lateral OFC to not winning. Importantly, during the reward anticipation phase of the monetary task, individuals aged 19 and 14 with higher depression severity scores showed lower medial OFC activation in the reward contrast (large-win minus no-win), but higher lateral OFC activation in the non-reward contrast (no-win minus large-win). Further, the activation of the medial OFC was negatively correlated with anhedonia, and the activation of the lateral OFC was correlated with negative feeling symptoms [33]. Interestingly, lower medial OFC activation was associated with current depression symptom scores, whereas higher lateral OFC activation was associated with both current and future depression scores.

Given the critical role of the medial OFC and VS in encoding specific stimulus-reward associations and predicting potential outcomes in goal-directed behaviors [5, 102], the pathologically lower activation of the medial OFC during reward anticipation in depressive patients may reflect a difficulty to develop associations between sensory features of stimuli and their reward value and therefore to predict reward outcomes. It is suggested that this insensitivity to reward cues produces the symptom of amotivation (loss of motivation) observed in depression [5, 100].

Reward outcomes and the loss of interest/pleasure in major depressive disorder: Individuals with MDD exhibited hyposensitivity

behaviorally to the delivery of reward stimuli or positive events in the reward outcome or consummatory phase of reward, and this was associated with blunted responses within frontostriatal circuitry involving the medial OFC [103]. For example, lower activations were found in the medial OFC (BA11) and VS/NAcc in adult patients with MDD when they listened to their favorite music [104], and in unmedicated recovered patients with a history of MDD when they tasted and viewed pleasant taste stimuli [105]. In terms of receiving monetary rewards, MDD patients also showed hypoactivation in the medial OFC, caudate, and ACC during high-magnitude reward feedback in a probabilistic task [101]. Thus, decreased activations in the medial OFC to the delivery of rewarding stimuli are implicated in MDD. Overall, the evidence in this section provides evidence that in response to reward outcomes, there is often lower activation in the medial OFC and in a region to which it connects, the ventral striatum, in MDD patients, and that this is associated with less subjective pleasure.

Reward prediction error and blunted associative learning in major depressive disorder: In line with reward anticipation and reward outcome brain differences in depression, reward prediction error in MDD patients is also linked to blunted activation in frontostriatal regions that include the medial OFC and VS. Using a standard reinforcement learning task, a group of unmedicated MDD patients had attenuated activations in the medial OFC compared to healthy controls when unexpected rewards were obtained [106]. Notably, the medial OFC and VS neural signals associated with positive reward PE were inversely correlated with anhedonia severity in depression patients (i.e., a lower positive reward prediction error was associated with greater anhedonia) (Fig. 3). Another study using a simulated slot-machine game found that MDD patients exhibited attenuated activations in the OFC, NAcc, and caudate in response to unexpected rewards [107]. Decreased activations in the OFC to positive reward prediction error could relate to deficits in stimulus to reward outcome associative learning that may impair hedonic capacity.

*Emotion regulation, the lateral orbitofrontal cortex, and negative bias*. The negative bias observed in depressive patients, which refers to more emphasis on negative than positive stimuli or information, has been linked to hyperactivation in the lateral OFC. For instance, in an emotional go/no-go task, depressed patients showed an enhanced neural response in the lateral OFC (BA47) to sad distractors compared to healthy controls, suggesting that irrelevant negative stimuli have a greater capacity to capture attention in depressed patients [108]. Moreover, disrupted activity and connectivity of the lateral OFC were also related to negative affective biases. Young individuals with (vs. without) a familial risk of depression showed enhanced activations in the lateral OFC and insula as well as lower activations in the ACC when viewing aversive stimuli [109]. Adolescent patients with depression also had greater activation in the amygdala, lateral OFC (peak coordinates: 41, 19, −16), and subgenual ACC in response to fearful expressions than healthy controls [110]. Moreover, when processing angry or sad faces, medication-free MDD patients had increased connectivity between the lateral OFC, dorsolateral prefrontal cortex (DLPFC), and the inferior frontal operculum [111]. Thus in the context of the roles of the lateral OFC in the representation of unpleasant stimuli and non-reward [38], the hyperactivation in the lateral OFC to such stimuli is proposed to underly the bias toward increased behavior to unpleasant stimuli observed in MDD [64]. Moreover, once started, those unpleasant states tend to persist in ruminating thoughts, which are ascribed to increased non-reward network attractor states in the lateral OFC, which are maintained in part and kept in memory by long-loop attractor neuronal networks that maintain neuronal firing both within the local network in the lateral OFC and by long loops to the angular gyrus [65, 112]. It is found that the activations to non-reward often extend laterally from the lateral OFC into regions that may be described as ventrolateral prefrontal cortex in the inferior frontal gyrus (IFG) [34]. One such region is 47l, which has strong connectivity with Broca's area 44 and 45, and is suggested to be a route by which the human lateral OFC can access language systems, allowing emotional experiences to be reported [12, 113].

### Connectivity differences of the orbitofrontal cortex in major depressive disorder

To start with functional connectivity (FC), of particular importance is that a resting state voxel-level functional connectivity analysis with a large sample of 421 MDD patients and 488 healthy controls showed that MDD patients had lower rsFC between the medial OFC (BA13) and memory-related regions (parahippocampal gyrus and medial temporal lobe), and higher rsFC between the lateral OFC (BA47/12) and brain regions related to the sense of self and agency (the precuneus) and language (i.e., angular gyrus) (Fig. 4) [65]. Given that the medial OFC is involved in representations of reward/pleasant stimuli and the lateral OFC of punishment/unpleasant/non-reward stimuli [32, 33] (Section "Introduction to the orbitofrontal cortex (OFC) and depression"), this is evidence that supports the attractor theory of depression [64], with depressed people having fewer happy memories and anhedonia related to the medial OFC, and more ruminating sad thoughts associated with the increased connectivity of the lateral OFC [65]. A series of further rsFC studies with a large sample size and cross-validation by replication with other patient samples further confirmed that MDD patients had decreased functional connectivity between the medial OFC (involved in emotion), and amygdala and fusiform gyrus, as well as increased connectivity between the lateral OFC and brain areas that include the posterior cingulate cortex (involved in memory), subcallosal ACC, language-related inferior frontal gyrus regions, and self-related precuneus [66, 67, 69–71] (see summary Fig. 5 for more details). Those discoveries of decreased FCs in medial OFC and increased FCs in lateral OFC in MDD provide a framework for understanding depression in the context of brain systems involved in emotion [5, 64, 112].

In addition, decreased connectivity between the medial OFC and limbic regions (e.g., the amygdala) has been consistently identified in MDD, and may be linked to the disrupted mood regulation. First, decreased functional connectivity between the medial OFC and amygdala has been consistently reported in MDD patients [71, 114]. A recent large-scale rsFC study with 336 MDD patients and 350 controls indicated a decreased rsFC between the amygdala and both the medial and lateral OFC in patients, and the reduction of connectivity strength of the medial OFC with the amygdala was correlated with the increase in depression symptoms and duration of illness [71]. Preclinical and clinical evidence suggests that the functional coupling of the OFC and the amygdala mediates the association between spontaneous reappraisal and emotional responses in emotional regulation [115], and that the disrupted connectivity between medial OFC and amygdala may relate to the depressed mood.

Moreover, higher connectivity between the lateral OFC and insula was identified in depressive individuals. A longitudinal study found that the OFC-insula connectivity strength in response to loss outcome in a reward task was positively correlated with prospective (9 months later) depressive symptoms [116], representing a vulnerability factor for depression. Moreover, young individuals with a familial risk of depression showed enhanced responses both in lateral OFC and insula when viewing aversive stimuli [109]. Interestingly, resting-state functional and structural connectivity work also identified increased connectivity between the lateral OFC and insula in MDD patients [117, 118]. Given the crucial role of the antero-ventral insula which is adjacent to and connected with the lateral orbitofrontal cortex in producing

autonomic responses [11, 119, 120], the abnormally increased connectivity between the lateral OFC and insula may be indicative of impaired integration of negative value with emotion-related autonomic responses. In addition to reduced medial OFC and striatal activity in the reward-related tasks as described above, several studies also indicate disrupted connectivity within fronto-striatal reward circuits implicated in MDD. For instance, MDD patients showed decreased rsFC mainly located in the cortical-striatal pathway, including the medial OFC, NAcc, rostral ACC, and caudate, relative to healthy controls [121].

### Metabolic and neurochemical differences of the orbitofrontal cortex in major depressive disorder

Imaging studies using positron emission tomography (PET) techniques have consistently identified glucose metabolic abnormalities across the cortical–limbic network spanning the OFC in MDD [122]. The abnormal physiological activity is relevant to pathological changes in synaptic transmission, such as serotonergic, dopaminergic, noradrenergic, glutamatergic, and GABAergic transmission. In the next section, the metabolic and neurochemical abnormalities of the OFC in depressed patients are considered, with a focus mainly on glucose metabolism and serotonergic systems.

*Glucose metabolism*. In most studies, MDD patients were characterized by increased medial and lateral OFC glucose metabolism in the depressed phase, which can be reversed by various antidepressant therapies such as classic and glutamatergic antidepressant drugs, deep brain stimulation (DBS), and transcranial magnetic stimulation (TMS) [123–126]. For instance, Drevets et al. (2002) found that unmedicated depressed patients had increased metabolism in the lateral OFC and amygdala relative to healthy controls at pre-treatment baseline, followed by a decrease after six months of antidepressant treatment [125]. Another longitudinal pharmacotherapy study also indicated that compared to non-responders, responders with successful treatment had a greater decrease towards normality of medial and lateral OFC glucose metabolism [123].

*Serotonergic system*. Due to the antidepressant effect of selective serotonin reuptake inhibitors and increased serotonin transmission produced by other antidepressant drugs, alterations of the central serotonergic (5-HT) system have drawn much attention in depression [127]. In PET imaging, it has been shown that MDD is associated with lower 5-$HT_{1A}$ receptor binding [128]. Consistent evidence is that tryptophan depletion that produces a reduction of central 5-HT transmission induces a transient return of depressive symptoms in remitted MDD patients, along with an increase in regional cerebral glucose utilization in the lateral OFC [129].

So far, we have described different abnormalities in depressive states related to the medial and lateral OFC, as summarized in Fig. 5. We highlight that lower connectivity and less activation to rewards of the medial OFC may be associated with the anhedonia symptom in MDD, whereas higher connectivity and more activation to non-rewards of the lateral OFC may be related to the negative bias in MDD. In the next section, we will focus on whether (and how) the medial and lateral OFC abnormalities underlying different depressive symptoms can be normalized by specific antidepressant interventions.

## ANTIDEPRESSANT INTERVENTIONS TARGETING THE ORBITOFRONTAL CORTEX

### Antidepressant medications

*Conventional antidepressants, the lateral orbitofrontal cortex, and negative bias*. Conventional antidepressants reduce negative

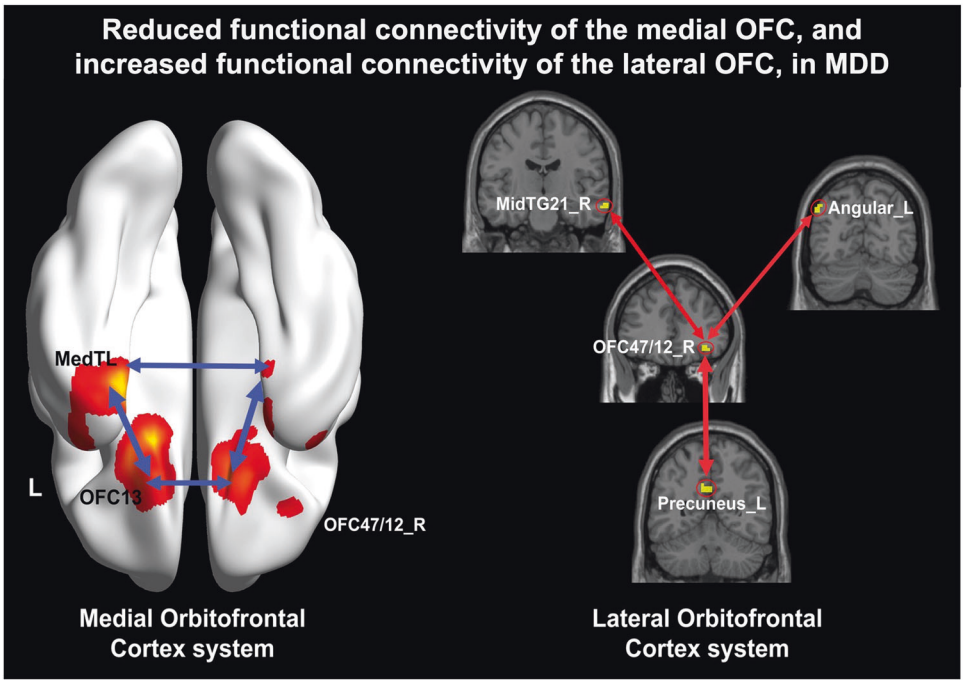


**Fig. 4 Abnormal resting-state voxel-level functional connectivity of the medial and lateral OFC in patients with major depression.** MDD patients showed decreased resting-state functional connectivity between the medial OFC and MedTL (arrows in blue in the left panel) and increased connectivity between the lateral OFC, left precuneus, left angular gyrus, and MidTG21_R (arrows in red in the right panel) relative to healthy controls. MedTL: medial temporal lobe from the parahippocampal gyrus to the temporal pole; MidTG21_R: right middle temporal gyrus area 21. This is from a pioneering brain-wide voxel-level association study (BWAS), which enabled voxels in the lateral orbitofrontal cortex and medial orbitofrontal cortex with different functional connectivity in depression to be identified without prior limiting hypotheses. The figure was modified with permission from Cheng et al., Medial reward and lateral non-reward orbitofrontal cortex circuits change in opposite directions in depression, Brain, 2016, 139:3296–309, Oxford University Press [65].

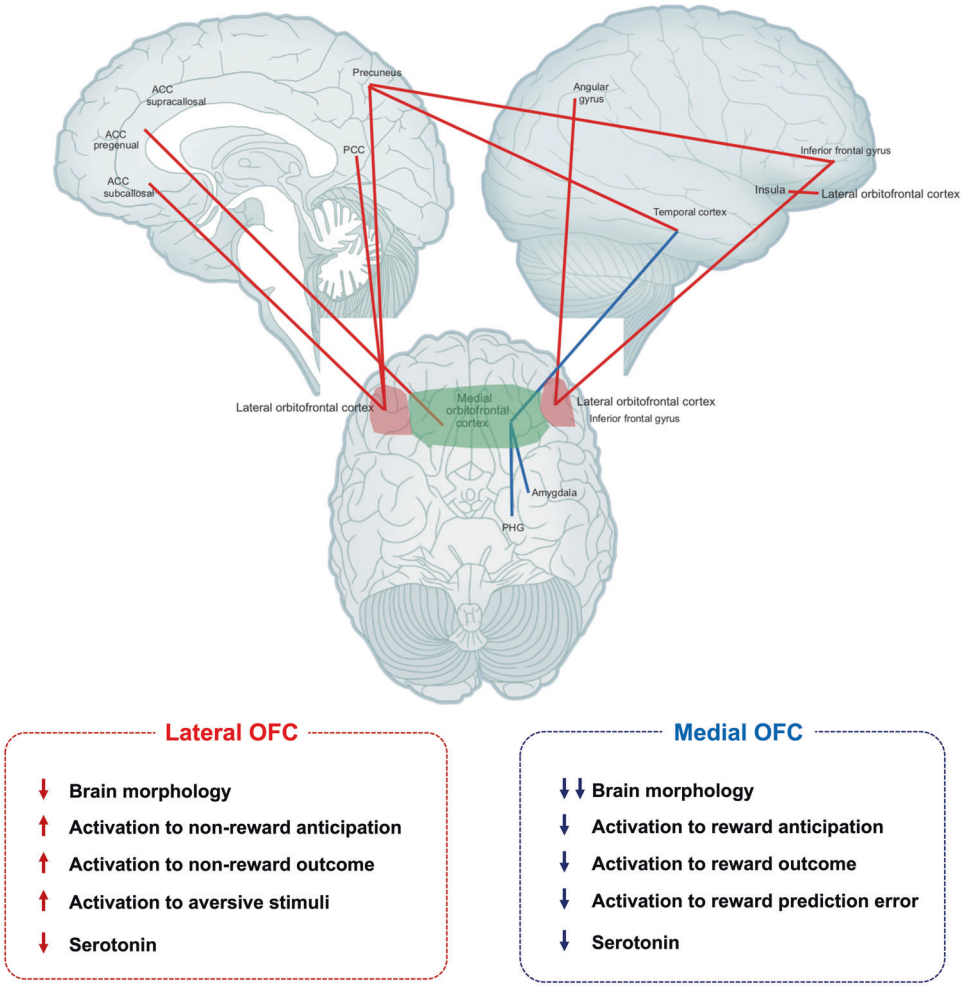


**Fig. 5 Summary of the abnormalities of the medial and lateral orbitofrontal cortex in major depressive disorder.** Above: Functional connectivity differences of the medial and lateral OFC in depression. Red lines connecting brain regions indicate higher functional connectivity in MDD than in controls, including higher connectivity of the lateral OFC with the anterior cingulate cortex (ACC, including the subcallosal part), posterior cingulate cortex (PCC), insula, inferior frontal gyrus (IFG), angular gyrus, and precuneus. Blue lines connecting brain regions indicate lower functional connectivity in MDD than in controls, including lower connectivity of the medial OFC with the amygdala, medial temporal cortex, parahippocampal gyrus, striatum, and temporal cortex. Below: Differences in brain structure (decreased volume or area) and in responses to reward, non-reward, and aversive stimuli, and in neurochemistry (especially serotonin) of the lateral and medial orbitofrontal cortex in major depression (see text for more details).

bias in depressed patients, and this may relate to a reversal of the oversensitivity and higher functional connectivity of the lateral OFC [65, 112]. For instance, an SSRI antidepressant (citalopram) resulted in a smaller activation in the lateral OFC in response to aversive stimuli (used to measure negative bias) in depressed patients [130]. Consistently, unmedicated depressed adolescents had significantly greater activation to fearful relative to neutral facial expressions than did healthy controls in the lateral OFC (peak coordinate: 41, 19, −16), subgenual ACC, and amygdala, and SSRI medication (fluoxetine) normalized this [110].

We emphasize that only the altered functional connectivity in the lateral OFC, but not the medial OFC, with other brain regions, can be normalized by conventional antidepressant drugs (Fig. 6B) [65, 112]. A series of large-scale cross-sectional studies showed that significantly increased functional connectivity between the lateral OFC (but not medial OFC) and the precuneus, PCC, IFG, angular gyrus, subgenual and supracallosal ACC was found in unmedicated depressed patients relative to controls, and that this abnormality was ameliorated back towards the values in controls in medicated patients [65–67, 69, 70], suggesting a normalization of dysfunctional connectivity of the lateral OFC, but not the medial OFC, by conventional antidepressant drugs. Taken together, all these findings provide evidence that conventional antidepressants, particularly SSRIs, alleviate negative bias in processing emotionally salient information in depression, and act by reversing the increased functional connectivity and responsiveness of the lateral OFC in depression [112] (Figs. 5 and 6B).

The proposal about the antidepressant action of conventional antidepressants on negative bias via the lateral OFC network is supported by the cognitive neuropsychological (CNP) model [131, 132], which was developed to understand the puzzling phenomenon of delayed clinical effects of antidepressants that produce biological but incomplete psychiatric changes in the first few hours after the first dose. As briefly summarized by Godlewska and Harmer [132] and Godlewska [131], the model proposed that two key processes are required before early biological effects can be translated into clinical improvement. The first one is a positive shift in the processing of emotionally salient information. This shift first occurs at the behavioral and neurological levels following a single antidepressant dose. Brain regions in which such changes were identified are the lateral OFC, amygdala, ACC, putamen, hippocampus, and prefrontal cortex regions [132]. Subsequently,

## Medial and lateral OFC in response to ketamine and conventional antidepressants

### A. Ketamine increases activation to reward in the MID task (left) and ketamine increases the connectivity of the medial OFC and decreases anhedonia (right)

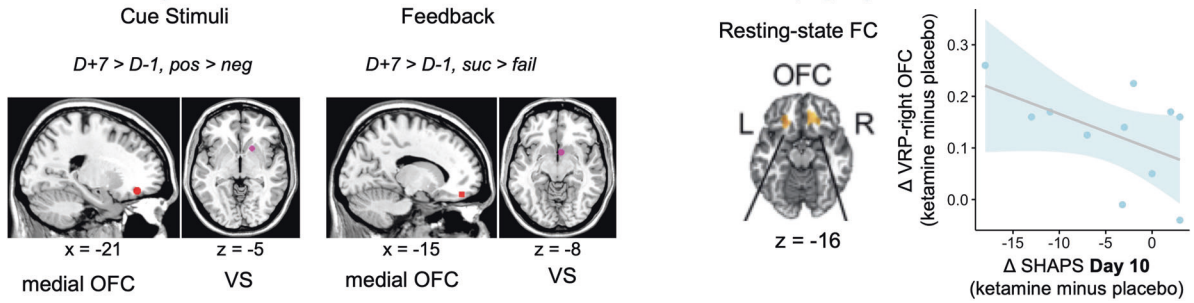


### B. Conventional antidepressants decrease the elevated functional connectivity of the lateral orbitofrontal cortex

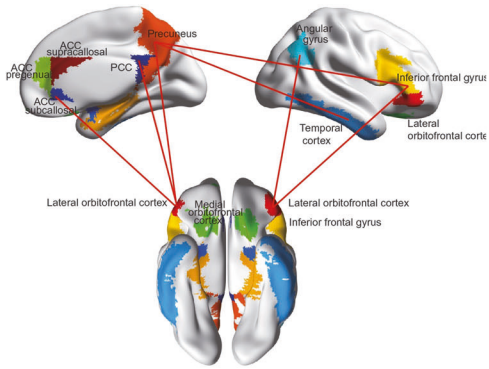


### C. Potential mechanisms for ketamine and conventional antidepressant medications

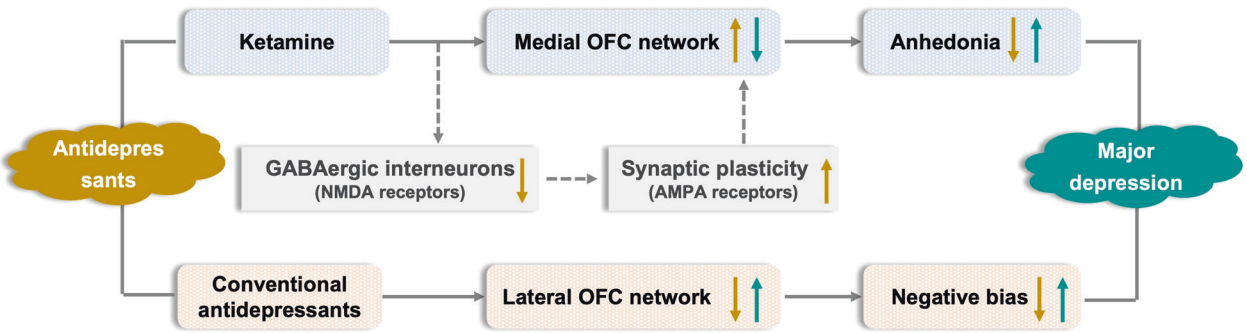


**Fig. 6 Summary of pathological abnormalities in the medial and lateral OFC in response to ketamine and to conventional antidepressant medications such as SSRIs. A** (Left panel) Ketamine administration induced sustained increases in the medial OFC (red dots) and nucleus accumbens activation (violet dots) during both reward anticipation and reward feedback phase of the monetary incentive delay task for TRD patients [135]. The dots represent spheres ROIs with the center point placed on the peak coordinates, and with a radius of 5 mm. (Right panel) Ketamine infusion increased the functional connectivity between medial OFC and ventral rostral putamen (VRP) for the TRD patients, and the increased magnitude of OFC-putamen connectivity correlated with improved levels of anhedonia symptoms (right panel, negative numbers indicate post-ketamine improvements compared with post-placebo) (Reproduced with permission from Mkrtchian A et al., Ketamine modulates fronto-striatal circuitry in depressed and healthy individuals, Molecular Psychiatry, 2021, 26(7):3292–3301, Springer Nature, Open Access [136]). **B** Conventional antidepressants such as SSRIs decrease the elevated functional connectivity of the lateral orbitofrontal cortex in depression (Reproduced with permission from Rolls ET et al., The orbitofrontal cortex: reward, emotion and depression, Brain Communications, 2020, 2(2):fcaa196, Oxford University Press, Open Access [112]). **C** Schematic presentation of potential mechanisms of action for ketamine and conventional SSRI antidepressant medications. Conventional antidepressants, particularly SSRIs, alleviate the negative bias by reversing the increased functional connectivity and responsiveness of the lateral OFC in MDD. Ketamine may act to increase the reduced functionality of the medial OFC in MDD to alleviate the anhedonia symptoms.

this new more positive bias will be 'enacted' through interactions with the social environment with repeated administration of antidepressant drugs. Therefore, conventional antidepressants may alleviate negative bias symptoms by treating abnormalities in the lateral OFC associated network.

*Ketamine, the medial orbitofrontal cortex, and anhedonia*. Drugs that influence glutamatergic transmission, e.g., ketamine, are effective in treating MDD and suicidal ideation with substantial clinical evidence [133, 134]. In particular, ketamine has shown remarkable consistency in ameliorating anhedonia symptoms, which might be associated with normalizing the pathological activity of reward circuits involving the medial OFC and VS. For instance, a pharmacological investigation recruited 10 treatment resistant depression (TRD) patients with a monetary incentive delay task before and after ketamine infusions. The study showed that ketamine administration (after seven days) induced a sustained increase in medial OFC and NAcc activation during both the anticipation of positive reward cues (OFC peak coordinates: −21, 38, −14) and during the receipt of positive feedback (the outcome phase) (OFC peak coordinates: −15, 47, −17). The enhanced reactivity of the medial OFC and NAcc was accompanied by decreased depression symptoms and better behavioral performance to positive items [135]. Given the blunted neural response in the medial OFC and VS during the reward task underlying the anhedonia symptom in depression described above, the increased activations in these two areas following ketamine administration potentially contribute to a recovery of the anhedonia symptoms in TRD, resulting in an improvement of depression symptoms.

Consistent with this, in one of the first clinical studies to investigate the anti-anhedonic mechanisms of ketamine in depression, 52 TRD patients received a single ketamine infusion. The primary outcome indicated that ketamine rapidly reduced levels of anhedonia, with a substantial effect within 40 minutes which lasted up to 3 days post-infusion. Importantly, in a subgroup of patients who received PET scans, the single ketamine infusion decreased glucose metabolism within OFC regions (the more medial part) (peak coordinates: 28, 46, −24; 34, 44, −14), and the reduced magnitude of the OFC metabolism was positively correlated with the changes in the anhedonia symptoms (i.e., changes in Snaith-Hamilton Pleasure Scale (SHAPS) scores) [126]. In addition, a recent double-blind, placebo-controlled, crossover trial in TRD and healthy controls also showed that ketamine infusion increased the functional connectivity between the right medial OFC (peak coordinates: 28, 26, 3) and ventral rostral putamen for the TRD patients toward the levels observed in healthy controls, and the increased magnitude of OFC-putamen connectivity was correlated with improved levels of anhedonia symptoms (i.e., reductions in SHAPS scores, Fig. 6A) [136]. Taken together, these findings provide evidence that ketamine has acute and chronic anti-anhedonic effects in MDD, which putatively are likely to be mediated by altered medial OFC and frontostriatal circuits (Fig. 6A).

The antidepressant mechanism of ketamine [95, 137] is potentially attributable to blocking N-methyl-D-aspartate (NMDA) receptors that mediate inhibition of inhibitory GABAergic interneurons in the PFC [138, 139]. The resulting increased release of glutamate leads to elevated α-amino-3-hydroxy-5-methyl-4-isoxazole propionic acid (AMPA) receptor activation, resulting in short- and long-term synaptic plasticity via activation of the brain-derived neurotrophic factor (BDNF) and via the mammalian target of rapamycin (mTOR) pathway [140]. The decreased inhibition and increased synaptic plasticity may promote increased neural activity in reward circuitry (including potentially the medial OFC) and/or an increased dopaminergic tone in the frontostriatal pathway [141] to reverse anhedonic symptoms. In the context that conventional antidepressant drugs (e.g., SSRIs) are inadequate to treat the anhedonia in MDD [142–144], glutamatergic drugs such as ketamine may be a more promising antidepressant to treat anhedonia. The hypothesis is thus that ketamine acts to increase the reduced functionality of the medial OFC in depression, so reducing the anhedonia symptoms (Fig. 6).

Other treatments that act to facilitate functional connectivity or activity of the medial orbitofrontal cortex would potentially be useful in the treatment of MDD. Another potential candidate is the group of drugs classified as psychedelics, such as psilocybin, which acts as non-selective serotonin 2 A receptor (5-HT2AR) agonist. One investigation found that treatment with psilocybin which produced antidepressant effects in treatment-resistant participants increased ventromedial prefrontal cortex resting state functional connectivity with the parietal cortex, and that the increase predicted a better response to the treatment measured at 5 weeks [145]. Although this is a study with a small sample size ($n = 15$), it does highlight the potential to find new classes of treatment that may act to increase the functional connectivity and/or activity of the medial OFC / anterior cingulate cortex region in the treatment of MDD.

**Brain stimulation therapies**

To reverse the abnormal activity and connectivity of the medial and lateral OFC in major depression, in addition to indirectly targeting the OFC through antidepressants, another promising therapeutic intervention is to directly target the OFC in brain stimulation therapies [58]. Encouraged by the oversensitive lateral OFC supported by 'non-reward attractor theory of depression' [64], several investigations have attempted to reduce the functioning of the lateral OFC using repetitive transcranial magnetic stimulation (rTMS) or DBS.

*Stimulation of the lateral orbitofrontal cortex using repetitive transcranial magnetic stimulation*. rTMS has been used as a relatively safe treatment that can alleviate symptoms of depressive patients in TRD. The treatment effect of conventional rTMS protocols targeting the DLPFC, or occasionally the dorsomedial prefrontal cortex (DMPFC), has a bimodal distribution [146]. Recently, rTMS that may influence the lateral OFC has also been employed in patients with TRD [74, 75, 147]. Lateral OFC-rTMS in depression was first reported in a case study [74]. In this study, a female with an eight-year history of MDD, who previously failed to respond to both DLPFC-rTMS and DMPFC-rTMS protocols, received 1-Hz rTMS targeting the right lateral OFC. After 30 sessions, the patient reported significant mood improvement and showed marked rsFC changes within the cortico-striatal-thalamic loop circuits, e.g., decreased connectivity between the lateral OFC and the NAcc. This investigation was followed by another study that employed the same lateral OFC-rTMS protocols in a larger sample of MDD (42 patients) [75], and found that nearly 25% of patients achieved remission overall, and this remission proportion was nearly identical among patients who did not respond to DMPFC-rTMS. Due to the lack of a sham control group, these two studies only provide preliminary evidence for an antidepressant effect of lateral OFC-rTMS. A more recent study showed that right orbitofrontal TMS benefits depressed patients unresponsive to DLPFC-TMS [147], consistent with the approach to depression reviewed here.

*Stimulation of the lateral orbitofrontal cortex using deep brain stimulation*. DBS is a promising therapeutic intervention for depression, particularly for TRD. DBS has been applied to brain regions within the frontostriatal and limbic circuits, such as the NAcc [148], subgenual ACC [149], lateral habenula [150], and ventral capsule (VC)/VS-amygdala loop [151]. A recent study demonstrated that DBS targeting the lateral OFC helps to alleviate mood symptoms in depression [76]. In this study, twenty-five TRD patients received high-frequency electrical stimulation across the

medial and lateral OFC, and other non-OFC brain regions such as the amygdala, insula, subgenual ACC, and dorsal cingulate cortex. The results indicated that locally, the lateral OFC stimulation suppressed low-frequency power—theta-and alpha-band—activity in the target region. The normalized OFC activity inversely correlated with the mood state during the stimulation period. Broadly at the neural network level, except for the target region, lateral OFC stimulation also suppressed theta-band activity, with the most remarkable effects in the insula and dorsal cingulate cortex. It is worth noting that mood improvement by stimulation of the lateral OFC was more effective than stimulation of the medial OFC and other non-OFC brain regions. Although replication of these observations with a larger sample size is required, they do suggest that the lateral OFC is a promising new therapeutic target for DBS to improve mood states by modulating mood-related circuits in TRD patients.

## SUMMARY AND FUTURE DIRECTIONS

The evidence described in this paper indicates the following, which is partly summarized in Figs. 5 and 6:

(1) In humans, the medial orbitofrontal cortex is implicated in rewards, and the lateral orbitofrontal cortex in punishment and non-reward;
(2) In major depressive disorder, there is evidence for reduced volume (or area or thickness) of the OFC especially the medial OFC; decreased activations to reward of the medial OFC linked to anhedonia; increased activations to non-reward/aversive events of the lateral OFC linked to negative bias; and decreased functional connectivity of the medial OFC and increased functional connectivity of the lateral OFC with other brain regions;
(3) Conventional antidepressants such as the SSRIs reduce the elevated activation/functional connectivity of the lateral OFC towards normal in MDD and reduce negative bias, but do not ameliorate the lower functional connectivity of the medial OFC and anhedonia.
(4) Treatments are therefore needed to increase the activation and connectivity of the medial OFC and to relieve the anhedonia in MDD, and emerging evidence suggests that ketamine may act in this way. Another potential class of drugs that may act in this way are the serotonin 2 A receptor agonists such a psilocybin.
(5) Further, in view of the above, the possibility of treating depression with a combination of drugs or other treatments that together work on both the lateral and the medial orbitofrontal cortex is described.

Some limitations help to show some future directions. For example, it is not yet clear exactly how ketamine acts to relieve depression. One finding is that ketamine blocks burst firing in the lateral habenula [61], but this was a rapid effect, and it is found in humans that ketamine at first produces schizophrenia-like symptoms of dissociation, and then hours later, an antidepressant effect is evident [61, 152]. However, the pathway from the orbitofrontal cortex to the habenula is a route via which effects on emotion and depression may be mediated [59]. Another issue is that although there is evidence that the anhedonia in depression is related to decreased reward processing in the medial orbitofrontal cortex (Section "Reward-related processing, the medial orbitofrontal cortex, and anhedonia"), and that the negative bias and responsiveness to non-reward is related to increased activation in the lateral orbitofrontal cortex (Section "Emotion regulation, the lateral orbitofrontal cortex, and negative bias", [33]), further research is needed on how these relate to the overall severity of the depression. In addition, we note that the focus of this paper has been on the orbitofrontal cortex in depression. We have described how it is connected to other brain regions involved in emotion in Section "Relation of the orbitofrontal cortex to other brain regions involved in emotion in humans ", and investigations of how these other brain regions are involved in depression are considered elsewhere, but we suggest relate to the orbitofrontal cortex systems described here [58, 112, 153]. Furthermore, although we have underscored the critical role of the OFC in depression, it is unlikely that depression can be solely attributed to impairments in a single brain region due to its complexity and heterogeneity. A number of other lines of evidence also suggest the importance of other brain regions, such as the subgenual cingulate cortex, amygdala, and ventral striatum, and targeting these brain regions also proves to be therapeutic for some depression patients [151]. More evidence is needed to examine how these other brain regions interact with the orbitofrontal cortex in MDD or different subtypes of MDD [114].

In conclusion, points 1–5 above provide evidence that the medial and lateral orbitofrontal cortex are key regions in depression and potentially for developing further treatments for depression.

## DATA AVAILABILITY

The data that were used to support the findings of this study are available from the corresponding author upon reasonable request.

## REFERENCES

1. The Lancet Global H. Mental health matters. Lancet Glob Health. 2020;8:e1352.
2. Vos T, Lim SSGDalC. Global burden of 369 diseases and injuries in 204 countries and territories, 1990–2019: a systematic analysis for the Global Burden of Disease Study 2019. Lancet. 2020;396:1204–22.
3. Rush AJ, Trivedi MH, Wisniewski SR, Nierenberg AA, Stewart JW, Warden D, et al. Acute and longer-term outcomes in depressed outpatients requiring one or several treatment steps: a STAR*D report. Am J Psychiatry. 2006;163:1905–17.
4. Rolls ET. The neuroscience of emotional disorders. Handb Clin Neurol. 2021;183:1–26.
5. Rolls ET. Emotion, motivation, decision-making, the orbitofrontal cortex, anterior cingulate cortex, and the amygdala. Brain Struct Funct. 2023;228:1201–57.
6. Ongür D, Ferry AT, Price JL. Architectonic subdivision of the human orbital and medial prefrontal cortex. J Comp Neurol. 2003;460:425–49.
7. Kringelbach ML, Rolls ET. The functional neuroanatomy of the human orbitofrontal cortex: evidence from neuroimaging and neuropsychology. Prog Neurobiol. 2004;72:341–72.
8. Rolls ET. The Orbitofrontal Cortex. Oxford: Oxford University Press; 2019.
9. Ongür D, Price JL. The organization of networks within the orbital and medial prefrontal cortex of rats, monkeys and humans. Cereb Cortex. 2000;10:206–19.
10. Kringelbach ML. The human orbitofrontal cortex: linking reward to hedonic experience. Nat Rev Neurosci. 2005;6:691–702.
11. Rolls ET, Deco G, Huang CC, Feng J. The human orbitofrontal cortex, vmPFC, and anterior cingulate cortex effective connectome: emotion, memory, and action. Cereb Cortex. 2022;33:330–56.
12. Rolls ET, Deco G, Huang CC, Feng J. Human amygdala compared to orbitofrontal cortex connectivity, and emotion. Prog Neurobiol. 2023;220:102385.
13. Kadohisa M, Rolls ET, Verhagen JV. Neuronal representations of stimuli in the mouth: the primate insular taste cortex, orbitofrontal cortex, and amygdala. Chem Senses. 2005;30:401–19.
14. Rolls ET, Critchley HD, Mason R, Wakeman EA. Orbitofrontal cortex neurons: role in olfactory and visual association learning. J Neurophysiol. 1996;75:1970–81.
15. Critchley HD, Rolls ET. Hunger and satiety modify the responses of olfactory and visual neurons in the primate orbitofrontal cortex. J Neurophysiol. 1996;75:1673–86.
16. Padoa-Schioppa C, Conen KE. Orbitofrontal cortex: A neural circuit for economic decisions. Neuron. 2017;96:736–54.
17. Padoa-Schioppa C. Neurobiology of economic choice: a good-based model. Annu Rev Neurosci. 2011;34:333–59.
18. Thorpe SJ, Rolls ET, Maddison S. The orbitofrontal cortex: neuronal activity in the behaving monkey. Exp Brain Res. 1983;49:93–115.
19. Rosenkilde CE, Bauer RH, Fuster JM. Single unit activity in ventral prefrontal cortex in behaving monkeys. Brain Res. 1981;209:375–94.
20. Baylis LL, Gaffan D. Amygdalectomy and ventromedial prefrontal ablation produce similar deficits in food choice and in simple object discrimination learning for an unseen reward. Exp Brain Res. 1991;86:617–22.

21. Noonan MP, Mars RB, Rushworth MF. Distinct roles of three frontal cortical areas in reward-guided behavior. J Neurosci: Off J Soc Neurosci. 2011;31:14399–412.
22. Rolls ET, Kringelbach ML, de Araujo IET. Different representations of pleasant and unpleasant odors in the human brain. Eur J Neurosci. 2003;18:695–703.
23. de Araujo IET, Kringelbach ML, Rolls ET, McGlone F. Human cortical responses to water in the mouth, and the effects of thirst. J Neurophysiol. 2003;90:1865–76.
24. de Araujo IET, Kringelbach ML, Rolls ET, Hobden P. The representation of umami taste in the human brain. J Neurophysiol. 2003;90:313–9.
25. Grabenhorst F, Rolls ET. Selective attention to affective value alters how the brain processes taste stimuli. Eur J Neurosci. 2008;27:723–9.
26. Grabenhorst F, Rolls ET, Parris BA, D'Souza A. How the brain represents the reward value of fat in the mouth. Cereb Cortex. 2010;20:1082–91.
27. Kringelbach ML, O'Doherty J, Rolls ET, Andrews C. Activation of the human orbitofrontal cortex to a liquid food stimulus is correlated with its subjective pleasantness. Cereb Cortex. 2003;13:1064–71.
28. Rolls ET, O'Doherty J, Kringelbach ML, Francis S, Bowtell R, McGlone F. Representations of pleasant and painful touch in the human orbitofrontal and cingulate cortices. Cereb Cortex. 2003;13:308–17.
29. McCabe C, Rolls ET, Bilderbeck A, McGlone F. Cognitive influences on the affective representation of touch and the sight of touch in the human brain. Soc, Cogn Affect Neurosci. 2008;3:97–108.
30. Rolls ET, Grabenhorst F, Franco L. Prediction of subjective affective state from brain activations. J Neurophysiol. 2009;101:1294–308.
31. Rolls ET, Grabenhorst F, Parris BA. Warm pleasant feelings in the brain. Neuroimage. 2008;41:1504–13.
32. O'Doherty J, Kringelbach ML, Rolls ET, Hornak J, Andrews C. Abstract reward and punishment representations in the human orbitofrontal cortex. Nat Neurosci. 2001;4:95–102.
33. Xie C, Jia T, Rolls ET, Robbins TW, Sahakian BJ, Zhang J, et al. Reward versus nonreward sensitivity of the medial versus lateral orbitofrontal cortex relates to the severity of depressive symptoms. Biol Psychiatry Cogn Neurosci Neuroimaging. 2021;6:259–69.
34. Rolls ET, Vatansever D, Li Y, Cheng W, Feng J. Rapid Rule-Based Reward Reversal and the Lateral Orbitofrontal Cortex. Cereb Cortex Commun. 2020;1:tgaa087.
35. O'Doherty J, Winston J, Critchley H, Perrett D, Burt DM, Dolan RJ. Beauty in a smile: the role of medial orbitofrontal cortex in facial attractiveness. Neuropsychologia. 2003;41:147–55.
36. Völlm BA, de Araujo IET, Cowen PJ, Rolls ET, Kringelbach ML, Smith KA, et al. Methamphetamine activates reward circuitry in drug naïve human subjects. Neuropsychopharmacology. 2004;29:1715–22.
37. Kringelbach ML, Rolls ET. Neural correlates of rapid reversal learning in a simple model of human social interaction. Neuroimage. 2003;20:1371–83.
38. Grabenhorst F, Rolls ET. Value, pleasure and choice in the ventral prefrontal cortex. Trends Cogn Sci. 2011;15:56–67.
39. Schuck NW, Cai MB, Wilson RC, Niv Y. Human orbitofrontal cortex represents a cognitive map of state space. Neuron. 2016;91:1402–12.
40. Knudsen EB, Wallis JD. Taking stock of value in the orbitofrontal cortex. Nat Rev Neurosci. 2022;23:428–38.
41. Rolls ET, Grabenhorst F, Deco G. Decision-making, errors, and confidence in the brain. J Neurophysiol. 2010;104:2359–74.
42. Rolls ET, Grabenhorst F, Deco G. Choice, difficulty, and confidence in the brain. Neuroimage. 2010;53:694–706.
43. Grabenhorst F, Rolls ET, Parris BA. From affective value to decision-making in the prefrontal cortex. Eur J Neurosci. 2008;28:1930–9.
44. Hornak J, O'Doherty J, Bramham J, Rolls ET, Morris RG, Bullock PR, et al. Reward-related reversal learning after surgical excisions in orbitofrontal and dorsolateral prefrontal cortex in humans. J Cogn Neurosci. 2004;16:463–78.
45. Hornak J, Bramham J, Rolls ET, Morris RG, O'Doherty J, Bullock PR, et al. Changes in emotion after circumscribed surgical lesions of the orbitofrontal and cingulate cortices. Brain. 2003;126:1691–712.
46. Hornak J, Rolls ET, Wade D. Face and voice expression identification in patients with emotional and behavioural changes following ventral frontal lobe damage. Neuropsychologia. 1996;34:247–61.
47. Fellows LK. Orbitofrontal contributions to value-based decision making: evidence from humans with frontal lobe damage. Ann N. Y Acad Sci. 2011;1239:51–8.
48. Noonan MP, Chau BKH, Rushworth MFS, Fellows LK. Contrasting Effects of Medial and Lateral Orbitofrontal Cortex Lesions on Credit Assignment and Decision-Making in Humans. J Neurosci. 2017;37:7023–35.
49. Rudebeck PH, Rich EL. Orbitofrontal cortex. Curr Biol. 2018;28:R1083–R8.
50. Rolls ET. The hippocampus, ventromedial prefrontal cortex, and episodic and semantic memory. Prog Neurobiol. 2022;217:102334.
51. Balleine BW, Leung BK, Ostlund SB. The orbitofrontal cortex, predicted value, and choice. Ann N. Y Acad Sci. 2011;1239:43–50.
52. Barreiros IV, Ishii H, Walton ME, Panayi MC. Defining an orbitofrontal compass: Functional and anatomical heterogeneity across anterior–posterior and medial–lateral axes. Behav Neurosci. 2021;135:165–73.
53. Stalnaker TA, Cooch NK, Schoenbaum G. What the orbitofrontal cortex does not do. Nat Neurosci. 2015;18:620–7.
54. Rolls ET. Brain Computations and Connectivity. Oxford: Oxford University Press; 2023.
55. LeDoux J, Brown R, Pine D, Hofmann S. Know thyself: well-being and subjective experience. Cerebrum: the Dana Forum on Brain Science. 2018;2018:cer-01-18.
56. LeDoux JE. Thoughtful feelings. Curr Biol. 2020;30:R619–R23.
57. Taschereau-Dumouchel V, Michel M, Lau H, Hofmann SG, LeDoux JE. Putting the "mental" back in "mental disorders": a perspective from research on fear and anxiety. Mol Psychiatry. 2022;27:1322–30.
58. Siddiqi SH, Schaper FL, Horn A, Hsu J, Padmanabhan JL, Brodtmann A, et al. Brain stimulation and brain lesions converge on common causal circuits in neuropsychiatric disease. Nat Hum Behav. 2021;5:1707–16.
59. Rolls ET. The roles of the orbitofrontal cortex via the habenula in non-reward and depression, and in the responses of serotonin and dopamine neurons. Neurosci Biobehav Rev. 2017;75:331–4.
60. Schultz W. Dopamine reward prediction error coding. Dialogues Clin Neurosci. 2022;18:23–32.
61. Yang Y, Cui Y, Sang K, Dong Y, Ni Z, Ma S, et al. Ketamine blocks bursting in the lateral habenula to rapidly relieve depression. Nature. 2018;554:317–22.
62. Proulx CD, Hikosaka O, Malinow R. Reward processing by the lateral habenula in normal and depressive behaviors. Nat Neurosci. 2014;17:1146–52.
63. Rolls ET, Deco G, Huang C-C, Feng J. The connectivity of the human frontal pole cortex, and a theory of its involvement in exploit vs explore. Cereb Cortex. 2023. e-pub ahead of print 21 November 2023; https://doi.org/10.1093/cercor/bhad416.
64. Rolls ET. A non-reward attractor theory of depression. Neurosci Biobehav Rev. 2016;68:47–58.
65. Cheng W, Rolls ET, Qiu J, Liu W, Tang Y, Huang C-C, et al. Medial reward and lateral non-reward orbitofrontal cortex circuits change in opposite directions in depression. Brain. 2016;139:3296–309.
66. Rolls ET, Cheng W, Du J, Wei D, Qiu J, Dai D, et al. Functional connectivity of the right inferior frontal gyrus and orbitofrontal cortex in depression. Soc Cogn Affect Neurosci. 2020;15:75–86.
67. Rolls ET, Cheng W, Gong W, Qiu J, Zhou C, Zhang J, et al. Functional connectivity of the anterior cingulate cortex in depression and in health. Cereb Cortex. 2019;29:3617–30.
68. Cheng W, Rolls ET, Ruan H, Feng J. Functional connectivities in the brain that mediate the association between depressive problems and sleep quality. JAMA Psychiatry. 2018;75:1052–61.
69. Cheng W, Rolls ET, Qiu J, Yang D, Ruan H, Wei D, et al. Functional connectivity of the precuneus in unmedicated patients with depression. Biol Psychiatry Cogn Neurosci Neuroimaging. 2018;3:1040–9.
70. Cheng W, Rolls ET, Qiu J, Xie X, Wei D, Huang C-C, et al. Increased functional connectivity of the posterior cingulate cortex with the lateral orbitofrontal cortex in depression. Transl Psychiatry. 2018;8:90.
71. Cheng W, Rolls ET, Qiu J, Xie X, Lyu W, Li Y, et al. Functional connectivity of the human amygdala in health and in depression. Soc Cogn Affect Neurosci. 2018;13:557–68.
72. Drevets WC. Orbitofrontal cortex function and structure in depression. Ann N. Y Acad Sci. 2007;1121:499–527.
73. Schmaal L, Hibar DP, Sämann PG, Hall GB, Baune BT, Jahanshad N, et al. Cortical abnormalities in adults and adolescents with major depression based on brain scans from 20 cohorts worldwide in the ENIGMA Major Depressive Disorder Working Group. Mol Psychiatry. 2017;22:900–9.
74. Fettes P, Peters S, Giacobbe P, Blumberger DM, Downar J. Neural correlates of successful orbitofrontal 1 Hz rTMS following unsuccessful dorsolateral and dorsomedial prefrontal rTMS in major depression: A case report. Brain Stimul. 2017;10:165–7.
75. Feffer K, Fettes P, Giacobbe P, Daskalakis ZJ, Blumberger DM, Downar J. 1Hz rTMS of the right orbitofrontal cortex for major depression: Safety, tolerability and clinical outcomes. Eur Neuropsychopharmacol. 2018;28:109–17.
76. Rao VR, Sellers KK, Wallace DL, Lee MB, Bijanzadeh M, Sani OG, et al. Direct electrical stimulation of lateral orbitofrontal cortex acutely improves mood in individuals with symptoms of depression. Curr Biol. 2018;28:3893–902. e4
77. Rajkowska G, Miguel-Hidalgo JJ, Dubey P, Stockmeier CA, Krishnan KRR. Prominent reduction in pyramidal neurons density in the orbitofrontal cortex of elderly depressed patients. Biol Psychiatry. 2005;58:297–306.
78. Rajkowska G, Miguel-Hidalgo JJ, Wei J, Dilley G, Pittman SD, Meltzer HY, et al. Morphometric evidence for neuronal and glial prefrontal cell pathology in major depression. Biol Psychiatry. 1999;45:1085–98.

79. Bremner JD, Vythilingam M, Vermetten E, Nazeer A, Adil J, Khan S, et al. Reduced volume of orbitofrontal cortex in major depression. Biol Psychiatry. 2002;51:273–9.
80. Lai T, Payne ME, Byrum CE, Steffens DC, Krishnan KR. Reduction of orbital frontal cortex volume in geriatric depression. Biol Psychiatry. 2000;48:971–5.
81. Grieve SM, Korgaonkar MS, Koslow SH, Gordon E, Williams LM. Widespread reductions in gray matter volume in depression. Neuroimage Clin. 2013;3:332–9.
82. Egger K, Schocke M, Weiss E, Auffinger S, Esterhammer R, Goebel G, et al. Pattern of brain atrophy in elderly patients with depression revealed by voxel-based morphometry. Psychiatry Res. 2008;164:237–44.
83. MacFall JR, Payne ME, Provenzale JE, Krishnan KR. Medial orbital frontal lesions in late-onset depression. Biol Psychiatry. 2001;49:803–6.
84. Webb CA, Weber M, Mundy EA, Killgore WDS. Reduced gray matter volume in the anterior cingulate, orbitofrontal cortex and thalamus as a function of mild depressive symptoms: a voxel-based morphometric analysis. Psychol Med. 2014;44:2833–43.
85. Cheng W, Rolls E, Gong W, Du J, Zhang J, Zhang X-Y, et al. Sleep duration, brain structure, and psychiatric and cognitive problems in children. Mol Psychiatry. 2021;26:3992–4003.
86. Gong W, Rolls ET, Du J, Feng J, Cheng W. Brain structure is linked to the association between family environment and behavioral problems in children in the ABCD study. Nat Commun. 2021;12:3769.
87. Du J, Rolls ET, Gong W, Cao M, Vatansever D, Zhang J, et al. Association between parental age, brain structure, and behavioral and cognitive problems in children. Mol Psychiatry. 2022;27:967–75.
88. Foland-Ross LC, Sacchet MD, Prasad G, Gilbert B, Thompson PM, Gotlib IH. Cortical thickness predicts the first onset of major depression in adolescence. Int J Dev Neurosci. 2015;46:125–31.
89. Admon R, Pizzagalli DA. Dysfunctional reward processing in depression. Curr Opin Psychol. 2015;4:114–8.
90. Borsini A, Wallis ASJ, Zunszain P, Pariante CM, Kempton MJ. Characterizing anhedonia: A systematic review of neuroimaging across the subtypes of reward processing deficits in depression. Cogn Affect Behav Neurosci. 2020;20:816–41.
91. Höflich A, Michenthaler P, Kasper S, Lanzenberger R. Circuit Mechanisms of Reward, Anhedonia, and Depression. Int J Neuropsychopharmacol. 2019;22:105–18.
92. Pizzagalli DA, Roberts AC. Prefrontal cortex and depression. Neuropsychopharmacology. 2022;47:609.
93. Wang S, Leri F, Rizvi SJ. Anhedonia as a central factor in depression: Neural mechanisms revealed from preclinical to clinical evidence. Prog Neuropsychopharmacol Biol Psychiatry. 2021;110:110289.
94. Der-Avakian A, Markou A. The neurobiology of anhedonia and other reward-related deficits. Trends Neurosci. 2012;35:68–77.
95. Pizzagalli DA. Toward a better understanding of the mechanisms and pathophysiology of anhedonia: Are we ready for translation? Am J Psychiatry. 2022;179:458–69.
96. Ward J, Lyall LM, Bethlehem RAI, Ferguson A, Strawbridge RJ, Lyall DM, et al. Novel genome-wide associations for anhedonia, genetic correlation with psychiatric disorders, and polygenic association with brain structure. Transl Psychiatry. 2019;9:327.
97. Zhang B, Lin P, Shi H, Öngür D, Auerbach RP, Wang X, et al. Mapping anhedonia-specific dysfunction in a transdiagnostic approach: an ALE meta-analysis. Brain Imaging Behav. 2016;10:920–39.
98. Zhang W-N, Chang S-H, Guo L-Y, Zhang K-L, Wang J. The neural correlates of reward-related processing in major depressive disorder: a meta-analysis of functional magnetic resonance imaging studies. J Affect Disord. 2013;151:531–9.
99. Ubl B, Kuehner C, Kirsch P, Ruttorf M, Diener C, Flor H. Altered neural reward and loss processing and prediction error signalling in depression. Soc Cogn Affect Neurosci. 2015;10:1102–12.
100. Park IH, Lee BC, Kim J-J, Kim JI, Koo M-S. Effort-based reinforcement processing and functional connectivity underlying amotivation in medicated patients with depression and schizophrenia. J Neurosci. 2017;37:4370–80.
101. Forbes EE, Christopher May J, Siegle GJ, Ladouceur CD, Ryan ND, Carter CS, et al. Reward-related decision-making in pediatric major depressive disorder: an fMRI study. J Child Psychol Psychiatry. 2006;47:1031–40.
102. Rolls ET. The orbitofrontal cortex and emotion in health and disease, including depression. Neuropsychologia. 2019;128:14–43.
103. Eshel N, Roiser JP. Reward and punishment processing in depression. Biol Psychiatry. 2010;68:118–24.
104. Osuch EA, Bluhm RL, Williamson PC, Théberge J, Densmore M, Neufeld RWJ. Brain activation to favorite music in healthy controls and depressed patients. Neuroreport. 2009;20:1204–8.
105. McCabe C, Cowen PJ, Harmer CJ. Neural representation of reward in recovered depressed patients. Psychopharmacology. 2009;205:667–77.
106. Rothkirch M, Tonn J, Köhler S, Sterzer P. Neural mechanisms of reinforcement learning in unmedicated patients with major depressive disorder. Brain. 2017;140:1147–57.
107. Segarra N, Metastasio A, Ziauddeen H, Spencer J, Reinders NR, Dudas RB, et al. Abnormal frontostriatal activity during unexpected reward receipt in depression and schizophrenia: relationship to anhedonia. Neuropsychopharmacology. 2016;41:2001–10.
108. Elliott R, Rubinsztein JS, Sahakian BJ, Dolan RJ. The neural basis of mood-congruent processing biases in depression. Arch Gen Psychiatry. 2002;59:597–604.
109. McCabe C, Woffindale C, Harmer CJ, Cowen PJ. Neural processing of reward and punishment in young people at increased familial risk of depression. Biol Psychiatry. 2012;72:588–94.
110. Tao R, Calley CS, Hart J, Mayes TL, Nakonezny PA, Lu H, et al. Brain activity in adolescent major depressive disorder before and after fluoxetine treatment. Am J Psychiatry. 2012;169:381–8.
111. Frodl T, Bokde ALW, Scheuerecker J, Lisiecka D, Schoepf V, Hampel H, et al. Functional connectivity bias of the orbitofrontal cortex in drug-free patients with major depression. Biol Psychiatry. 2010;67:161–7.
112. Rolls ET, Cheng W, Feng J. The orbitofrontal cortex: reward, emotion and depression. Brain Commun. 2020;2:fcaa196.
113. Rolls ET, Deco G, Huang CC, Feng J. The human language effective connectome. Neuroimage. 2022;258:119352.
114. Connolly CG, Ho TC, Blom EH, LeWinn KZ, Sacchet MD, Tymofiyeva O, et al. Resting-state functional connectivity of the amygdala and longitudinal changes in depression severity in adolescent depression. J Affect Disord. 2017;207:86–94.
115. Gao W, Biswal B, Chen S, Wu X, Yuan J. Functional coupling of the orbitofrontal cortex and the basolateral amygdala mediates the association between spontaneous reappraisal and emotional response. Neuroimage. 2021;232:117918.
116. Jin J, Narayanan A, Perlman G, Luking K, DeLorenzo C, Hajcak G, et al. Orbitofrontal cortex activity and connectivity predict future depression symptoms in adolescence. Biol Psychiatry Cogn Neurosci Neuroimaging. 2017;2:610–8.
117. Avery JA, Drevets WC, Moseman SE, Bodurka J, Barcalow JC, Simmons WK. Major depressive disorder is associated with abnormal interoceptive activity and functional connectivity in the insula. Biol Psychiatry. 2014;76:258–66.
118. Long Z, Duan X, Wang Y, Liu F, Zeng L, Zhao J-P, et al. Disrupted structural connectivity network in treatment-naive depression. Prog Neuropsychopharmacol Biol Psychiatry. 2015;56:18–26.
119. Rolls ET, Deco G, Huang CC, Feng J. Prefrontal and somatosensory-motor cortex effective connectivity in humans. Cereb Cortex. 2023;33:4939–63.
120. Baylis LL, Rolls ET, Baylis GC. Afferent connections of the caudolateral orbitofrontal cortex taste area of the primate. Neuroscience. 1995;64:801–12.
121. Gong L, Yin Y, He C, Ye Q, Bai F, Yuan Y, et al. Disrupted reward circuits is associated with cognitive deficits and depression severity in major depressive disorder. J Psychiatr Res. 2017;84:9–17.
122. Mayberg HS. Modulating dysfunctional limbic-cortical circuits in depression: towards development of brain-based algorithms for diagnosis and optimised treatment. Br Med Bull. 2003;65:193–207.
123. Brody AL, Saxena S, Silverman DH, Alborzian S, Fairbanks LA, Phelps ME, et al. Brain metabolic changes in major depressive disorder from pre- to post-treatment with paroxetine. Psychiatry Res. 1999;91:127–39.
124. Drevets WC, Videen TO, Price JL, Preskorn SH, Carmichael ST, Raichle ME. A functional anatomical study of unipolar depression. J Neurosci. 1992;12:3628–41.
125. Drevets WC, Bogers W, Raichle ME. Functional anatomical correlates of antidepressant drug treatment assessed using PET measures of regional glucose metabolism. Eur Neuropsychopharmacol. 2002;12:527–44.
126. Lally N, Nugent AC, Luckenbaugh DA, Niciu MJ, Roiser JP, Zarate CA Jr. Neural correlates of change in major depressive disorder anhedonia following open-label ketamine. J Psychopharmacol. 2015;29:596–607.
127. Xu C, Ma X-M, Chen H-B, Zhou M-H, Qiao H, An S-C. Orbitofrontal cortex 5-HT2A receptor mediates chronic stress-induced depressive-like behaviors and alterations of spine density and Kalirin7. Neuropharmacology. 2016;109:7–17.
128. Sargent PA, Kjaer KH, Bench CJ, Rabiner EA, Messa C, Meyer J, et al. Brain serotonin1A receptor binding measured by positron emission tomography with [11C] WAY-100635: effects of depression and antidepressant treatment. Arch Gen Psychiatry. 2000;57:174–80.
129. Neumeister A, Nugent AC, Waldeck T, Geraci M, Schwarz M, Bonne O, et al. Neural and behavioral responses to tryptophan depletion in unmedicated patients with remitted major depressive disorder and controls. Arch Gen Psychiatry. 2004;61:765–73.
130. McCabe C, Mishor Z, Cowen PJ, Harmer CJ. Diminished neural processing of aversive and rewarding stimuli during selective serotonin reuptake inhibitor treatment. Biol Psychiatry. 2010;67:439–45.

131. Godlewska BR. Cognitive neuropsychological theory: Reconciliation of psychological and biological approaches for depression. Pharm Ther. 2019;197:38–51.
132. Godlewska BR, Harmer CJ. Cognitive neuropsychological theory of antidepressant action: a modern-day approach to depression and its treatment. Psychopharmacology. 2021;238:1265–78.
133. Aan Het Rot M, Zarate CA Jr, Charney DS, Mathew SJ. Ketamine for depression: where do we go from here? Biol Psychiatry. 2012;72:537–47.
134. Wilkinson ST, Ballard ED, Bloch MH, Mathew SJ, Murrough JW, Feder A, et al. The effect of a single dose of intravenous ketamine on suicidal ideation: A systematic review and individual participant data meta-analysis. Am J Psychiatry. 2018;175:150–8.
135. Sterpenich V, Vidal S, Hofmeister J, Michalopoulos G, Bancila V, Warrot D, et al. Increased reactivity of the mesolimbic reward system after ketamine injection in patients with treatment-resistant major depressive disorder. Anesthesiology. 2019;130:923–35.
136. Mkrtchian A, Evans JW, Kraus C, Yuan P, Kadriu B, Nugent AC, et al. Ketamine modulates fronto-striatal circuitry in depressed and healthy individuals. Mol Psychiatry. 2021;26:3292–301.
137. Klein ME, Grice AB, Sheth S, Go M, Murrough JW. Pharmacological Treatments for Anhedonia. Curr Top Behav Neurosci. 2022;58:467–89.
138. Zanos P, Gould TD. Mechanisms of ketamine action as an antidepressant. Mol Psychiatry. 2018;23:801–11.
139. Zanos P, Moaddel R, Morris PJ, Riggs LM, Highland JN, Georgiou P, et al. Ketamine and Ketamine Metabolite Pharmacology: Insights into Therapeutic Mechanisms. Pharm Rev. 2018;70:621–60.
140. Zanos P, Gould TD. Intracellular signaling pathways involved in (S)- and (R)-ketamine antidepressant actions. Biol Psychiatry. 2018;83:2–4.
141. Kokkinou M, Ashok AH, Howes OD. The effects of ketamine on dopaminergic function: meta-analysis and review of the implications for neuropsychiatric disorders. Mol Psychiatry. 2018;23:59–69.
142. McClintock SM, Husain MM, Wisniewski SR, Nierenberg AA, Stewart JW, Trivedi MH, et al. Residual symptoms in depressed outpatients who respond by 50% but do not remit to antidepressant medication. J Clin Psychopharmacol. 2011;31:180–6.
143. McMakin DL, Olino TM, Porta G, Dietz LJ, Emslie G, Clarke G, et al. Anhedonia predicts poorer recovery among youth with selective serotonin reuptake inhibitor treatment-resistant depression. J Am Acad Child Adolesc Psychiatry. 2012;51:404–11.
144. Rizvi SJ, Grima E, Tan M, Rotzinger S, Lin P, McIntyre RS, et al. Treatment-resistant depression in primary care across Canada. Can J Psychiatry. 2014;59:349–57.
145. Carhart-Harris RL, Roseman L, Bolstridge M, Demetriou L, Pannekoek JN, Wall MB, et al. Psilocybin for treatment-resistant depression: fMRI-measured brain mechanisms. Sci Rep. 2017;7:13187.
146. Fitzgerald PB, Hoy KE, Anderson RJ, Daskalakis ZJ. A study of the pattern of response to rTMS treatment in depression. Depress Anxiety. 2016;33:746–53.
147. Prentice A, Kolken Y, Tuttle C, van Neijenhof J, Pitch R, van Oostrom I, et al. 1Hz right orbitofrontal TMS benefits depressed patients unresponsive to dorsolateral prefrontal cortex TMS. Brain Stimul. 2023;16:1572–5.
148. Bewernick BH, Hurlemann R, Matusch A, Kayser S, Grubert C, Hadrysiewicz B, et al. Nucleus accumbens deep brain stimulation decreases ratings of depression and anxiety in treatment-resistant depression. Biol Psychiatry. 2010;67:110–6.
149. Lozano AM, Mayberg HS, Giacobbe P, Hamani C, Craddock RC, Kennedy SH. Subcallosal cingulate gyrus deep brain stimulation for treatment-resistant depression. Biol Psychiatry. 2008;64:461–7.
150. Sartorius A, Kiening KL, Kirsch P, von Gall CC, Haberkorn U, Unterberg AW, et al. Remission of major depression under deep brain stimulation of the lateral habenula in a therapy-refractory patient. Biol Psychiatry. 2010;67:e9–e11.
151. Scangos KW, Khambhati AN, Daly PM, Makhoul GS, Sugrue LP, Zamanian H, et al. Closed-loop neuromodulation in an individual with treatment-resistant depression. Nat Med. 2021;27:1696–700.
152. Gärtner M, Weigand A, Meiering MS, Weigner D, Carstens L, Keicher C, et al. Region-and time-specific effects of ketamine on cerebral blood flow: a randomized controlled trial. Neuropsychopharmacology. 2023;48:1735–41.
153. Hamani C, Mayberg H, Stone S, Laxton A, Haber S, Lozano AM. The subcallosal cingulate gyrus in the context of major depression. Biol Psychiatry. 2011;69:301–8.

## ACKNOWLEDGEMENTS

This work was partly supported by the grant from the National Key R&D Program of China (No. 2019YFA0709502 to JF), the grant from Shanghai Municipal Science and Technology Major Project (No. 2018SHZDZX01 to JF), ZJ Lab, and Shanghai Center for Brain Science and Brain-Inspired Technology, the grant from the 111 Project (No. B18015 to JF). This work was partly supported by the grants from the National Natural Sciences Foundation of China (No. 82071997 to WC) and the Shanghai Rising-Star Program (No. 21QA1408700 to WC). This work was supported by the project from China Postdoctoral Science Foundation (No. 2022M710804 to BZ).

## AUTHOR CONTRIBUTIONS

BZ, WC, and JF conceived and designed the experiment. BZ drafted the manuscript with contributions from ETR, and comments from XW and CX. All authors read and approved the final manuscript.

## COMPETING INTERESTS

The authors declare no competing interests.

## ADDITIONAL INFORMATION

**Supplementary information** The online version contains supplementary material available at https://doi.org/10.1038/s41380-023-02380-w.

**Correspondence** and requests for materials should be addressed to Edmund T. Rolls, Wei Cheng or Jianfeng Feng.

**Reprints and permission information** is available at http://www.nature.com/reprints

**Publisher's note** Springer Nature remains neutral with regard to jurisdictional claims in published maps and institutional affiliations.

Springer Nature or its licensor (e.g. a society or other partner) holds exclusive rights to this article under a publishing agreement with the author(s) or other rightsholder(s); author self-archiving of the accepted manuscript version of this article is solely governed by the terms of such publishing agreement and applicable law.